

Alma Mater Studiorum – Università di Bologna

DOTTORATO DI RICERCA IN

Scienze Chirurgiche

Ciclo Trentesimo (XXX)

Settore Concorsuale: 06/F4

Settore Scientifico Disciplinare: MED/33

TITOLO TESI

**Unstable Fractures of the Forearm: a project to improve clinical
comprehension and to evaluate the results of the Interosseous
Membrane Reconstruction**

Presentata da: Dott. Cavaciocchi Michele

Coordinatore Dottorato

Supervisore

Prof.ssa Annalisa Patrizi

Prof. Andrea Stella

Esame finale anno 2018

Unstable Fractures of the Forearm: a project to improve clinical comprehension and to evaluate the results of the Interosseous Membrane Reconstruction

ABSTRACT

BACKGROUND:

The relevance of the Unstable Fractures of the Forearm treatment has emerged in the Literature just in the last four years, with more and more articles treating this complex subject; till now, few scientific evidences grew up. The Essex-Lopresti lesion represents the worse pattern of the Unstable Fractures of the Forearm, because of the three constraints disruption, so it can be defined as the most challenging forearm lesion for the surgeon. All the Authors agree to consider acute treatment as absolutely necessary to avoid all the problems deriving from the chronic pictures, pointing out the need for an early correct diagnosis of these diseases. Several surgical techniques are now described for the treatment of these triarticular lesions, but it's impossible to find a consensus on the most valid one, because of the exiguity of the treated patients numbers; different devices have been described as useful in the IOM reconstruction, but a true superiority can't be found.

METHODS:

I analyzed the database of the Orthopedic Unit of Faenza Hospital, evaluating the cases of Unstable Fractures of the Forearm: in the period between 2010 and 2016, ten patients have been treated, all male, with a mean age of 37 years; all the injuries had been caused by high energy trauma. Eight cases were chronic Essex-Lopresti injuries, two cases were acute. All these patients underwent an Interosseous Membrane Reconstruction (IOM), with different devices (frozen allograft, LARS, Ethibond braid and Ultratape).

RESULTS:

At a mean follow up of 22 months, the mean ROM for the acute cases was 5-140 degrees in flexion-extension, 68-0-66° degrees in pronation and supination, with no wrist functional limitations; the mean ROM in the chronic cases was 24-127 degrees in extension and flexion, 54-0-47 degrees in pronation and supination, 58 degrees in wrist extension and 63 degrees in wrist flexion, without impairment in the wrist movement in the ulnar and radial direction. At the same mean follow up, the mean Mayo Clinic Elbow Performance Score were 89/100 points for the chronic cases, result that can be defined as good, and 97,5/100 points for two acute cases (MEPS result 100 and 95 respectively), confirming the improvement of the functional results in the acutely treated patients. No wrist pain persistence was referred, but we pointed out three quick radial neck resorptions, that are not infrequent in the radial head prosthesis (metal monopolar and bipolar implants) with the new press-fit design, as widely stated by the recent Literature.

CONCLUSIONS:

The IOM plasty is a well planned technique and many Authors agree on its use both in acute and chronic conditions, but the results, in the Literature, are still exiguous and not homogeneous. Furthermore the progression of partial IOM tears is still unknown, like the existence of forearm microinstability that creates condral erosion of the capitellum and stem loosening in the radial head prostheses. Our encouraging data induce us to continue on the undertaken road, with the aim of validating the current surgical technique and, if possible, of improving it increasingly.

TITLE

Unstable Fractures of the Forearm: a project to improve clinical comprehension and to evaluate the results of the Interosseous Membrane Reconstruction

INDEX

Chapter 1: Introduction

1.1 The Forearm Unit: Anatomy and Biomechanics

1.2 Classification of the Unstable Fractures of the Forearm

1.3 The Elbow Instability

1.3.1 Simple Instability of the Elbow

a) Biomechanics of the lesions

b) Biomechanics of Elbow Instability

c) Elbow Dislocation Clinical Examination

1.3.2 Complex Instability of the Elbow

a) Bony Elbow Stabilizers

b) Radial Head

c) Olecranon

d) Coronoid

Chapter 2: The clinical-radiological assessment of the Essex Lopresti syndrome

2.1 Clinical Assessment

2.2 Imaging

2.3 The Longitudinal-Transversal Instability Manoeuvres

Chapter 3: Surgical options in the Unstable Fractures of the Forearm

3.1 Acute Essex Lopresti Syndrome

3.2 Notes on the Radial Head prosthesis

3.3 Chronic Essex-Lopresti Syndrome

Chapter 4: Clinical experience in the Unstable Fractures of the Forearm

4.1 Definition of the study

4.2 Clinical experience and results in Faenza Hospital Orthopedic Unit

4.3 Literature review

4.4 Discussion

4.5 Conclusions

References

CHAPTER 1:

Introduction

The first paper in the Literature, discussing the forearm instability after radial head excision, was written by Curr and Coe in 1946 [1], even if other Authors had previously described this condition [2]. In 1951 Peter Essex Lopresti described the proximal migration of the radius following the surgical excision of a comminuted Radial Head fracture, produced by a traumatic axial load from the wrist to the elbow with disruption of the Distal Radio-Ulnar Joint (DRUJ) and with rupture of the Interosseous Membrane. Thanks to this detailed description this injury gained the eponym of Essex Lopresti Syndrome [3]. Nowadays the Essex Lopresti Syndrome, like other traumatic patterns, can be classified into the group of Unstable Fractures of the Forearm, which are characterized by the intra-extrarticular fracture of one or both the forearm bones, associated with the instability of almost two of the three forearm constraints: the Proximal Radio-Ulnar Joint (PRUJ), the Distal Radio-Ulnar Joints (DRUJ) and the Interosseous Membrane (IOM); these anatomical and functional structures create the Forearm Unit. In the following discussion we'll review the anatomy and the biomechanics of the forearm functional unit, the classifications of the Unstable Fractures of the Forearm, the Essex Lopresti clinical-radiological assesment and its surgical treatments.

1.1 The Forearm Unit: Anatomy and Biomechanics

The forearm can be considered as a single articulating joint, where the interdependence of the different anatomical structures allows forearm rotation and elbow and wrist motion [4, 5]. These functions, especially the pronation and the supination, explain the complex integrated relationships between bones and soft tissues along the entire forearm length.

A complete knowledge of the biomechanics is essential for the correct management of the Unstable Fractures of the Forearm. Analyzing the elbow-forearm kinematic, we have to carefully consider the role of stabilizers both for flexion-extension and pronation-supination. The Lateral Ulnar Collateral Ligament (LUCL) and the Medial Collateral Ligament (MCL) stabilize the elbow in flexion-extension; the Annular Ligament, the Squared Ligament (also called Denucè Ligament), the Interosseous Membrane and the Triangular Ligament control the forearm pronation and supination. Annular and Denucè Squared ligaments are the stabilizers of Proximal Radio-Ulnaris Joint (PRUJ). Interosseous Membrane (IOM) is an extrarticular complex stabilizer of the forearm unit midportion. The anatomical studies find an agreement describing the IOM as composed by five ligamentous components: Proximal Oblique Weitbrecht Cord, Dorsal Oblique Accessory Cord, Central Band, Accessory Band, Distal Oblique Bundle. The two proximal ligaments (Proximal Oblique Cord and Dorsal Oblique Accessory Cord) contrast the Radial Head anterior dislocation [6] and change substabtiially in length, if compared with the distal three ligaments (Central Band, Accessory Band and Distal Oblique Bundle) [7], that are isometric, because the ulnar attachments are located almost on the axis of the forearm rotation. The Central Band (CB) is the most important IOM portion: it is approximatively 17 mm x 10.6 cm and its mechanical resistance (13.1 +/- 3.0 N/mm) is stronger than all the other part of the IOM; CB has a tenisle modulus of 608.1 +/- 160.2 mPa, its elongation at breaking point is 9.0 +/- 2.0% [8] and it has an istological composition made of Collagene for the 84% (an intermedate structure between membrane and ligament). CB arises from the inner ridge of radial diaphysis (about 7.7 cm from RH) and steers to the junction between the middle and the distal third of the ulna (13.2 cm from the olecranon tip) [9], with an oblique angle of 20-25° compared to the ulnar axis. The Distal Oblique Bundle (DOB) can be found in the 40% of human subjects, it arises from the inner part of distal ulnar diaphysis and it runs, with an opposite obliquity than CB, to the ulnar side of radial metaphisys. The DOB

gives a contribution in the stabilization of the distal radioulnar joint [7] and it contrasts the longitudinal migration of the ulna. Triangular Fibrocartilage (TFCC) is an intrarticular suspensor ligament of the Distal Radio-Ulnar Joint (DRUJ). The biomechanical role of IOM and TFCC is to maintain the axial forearm stability: after an experimental RH excision, the forearm stability is provided by the IOM for the 71% and by the TFCC for the 8%; from these considerations, it's easy to understand how a significant proximal migration of the radius occurs if radial head and both IOM and TFCC are disrupted.

The Forearm Ligaments have an function: to stabilize the two bones in the transverse and in the longitudinal plane, by transferring loads from the radius to the ulna. Radius and ulna are roughly parallel and connected, at each end, by a well-constrained joint, and, in the midportion, by the IOM. The system is relatively tight and is difficult to injure one of these structures without affecting another part of the system. Ulnar anatomy is relatively simple, contrary to the radius, that has a more complex structure: Sage pointed out the angles and curves complexity of the radial bone [10]. The Radius has four small but significant curves: two on the frontal plane (about 13° proximally and 6° in the middle shaft) and two in the sagittal plane (about 13° proximally and 9° in the middle shaft). These curves give it the typical "bow shape", that represent the biomechanical condition to cross over the Ulna in pronation, maintaining, at the same time, a relative tension of the IOM in all the positions. Schemitsch and Richards [11] confirmed the importance of the radial bow restoration to warrant a correct forearm function after a fracture. If the radial curves are not anatomically reconstructed, the forearm loses the possibility to achieve the full pronation and a good grip strength. The normal range of motion has been described as 71°-75° of pronation and 82°-84° of supination, with the ulna essentially fixed by its proximal anatomy (ulno-humeral joint) and the radius capable of a large movement at the DRUJ, drawing in the space a simple cone, with its axis running roughly from the center of the radial head to the center of the distal part of the ulna. . Two conditions must be fulfilled to allow a correct movement in pronation and supination: an equal longitudinal length of radius and ulna, with normal location and amount of the radial bow, and a stable relationship between the radius and ulna at the proximal, middle and distal radio-ulnar joints.

1.2 Classification of the Unstable Fractures of the Forearm

In 2007 Marc Soubeyrand [12] described the "Three Forearm Constraints" concept: The Forearm Unit must be interpreted like an association of three constraints, PRUJ, IOM and DRUJ, each one fundamental for the stability and, consequently, for the movement of the forearm itself. The lesion of one constraint (distal radius fracture, simple RH fracture, sinostosis) causes a decrease in pronation and supination, without instability (Soubeyrand's Stage 1). The loss of two constraints creates a partial transverse instability (Criss-Cross injury, Galeazzi lesion, Monteggia lesion, Soubeyrand's Stage 2). The lesion of all the three forearm constraints brings to a longitudinal and transverse forearm instability (Essex-Lopresti Lesion, Soubeyrand's Stage 3). The latter two patterns (Criss-Cross, Galeazzi, Monteggia and Essex Lopresti Lesions) define the "Unstable Fractures of the Forearm".

If we consider the onset timing, an Essex Lopresti Lesion can be acute or chronic: an immediate proximal translation larger than 5 mm. associated with a multi-fragmented Radial Head fracture is significative for an acute complete irreparable IOM laceration. A progressive radial migration after a proximal resection (more than 4 weeks from the trauma) or a painfull RH prostheses with DRUJ instability/discomfort and grip weakness is significative for a chronic Essex Lopresti injury, where we can suppose a partial IOM tear at the beginning, that became a complete tear after the repetitive tractions of the Biceps Brachii [13-15]. The last pattern has been named "Missed Essex Lopresti" by Jungbluth [16]: this definition started a discussion in

the Literature around the early loosening and the painful RH prostheses, as a clinical expression of a missed diagnosis of forearm instability. In 2006 Pfaeffle [17] described the Ligamentoplasty (IOM reconstruction) as a way to decrease the loads applied by a radial head prostheses to the capitellum. Recently Duckworth [18] presented a case series with a 28% of RH prostheses loosening in a six year follow up, that he hypothesized could be caused by a forearm microinstability. Some Authors (Soubeyrand, Pfaeffle, Jungbluth, Osterman [12, 16, 17, 19]) recommend a Ligamentoplasty in acute and chronic longitudinal instability of the forearm. The IOM reconstruction both in acute and chronic Essex Lopresti lesions can correct macro deformities and instability (ulnar plus at DRUJ, radial migration at PRUJ) or micro deformities and progressive instabilities (painful RH reconstruction or substitution by capitellum cartilage erosion, wrist discomfort).

1.3 The Elbow Instability

1.3.1 Simple Instability of the Elbow

The elbow is the second joint of the human body in order of dislocation frequency in adults, but, in the childhood, is the most dislocating joint; the elbow stability is warranted by a complex equilibrium, that a lot of injury patterns can break. The anatomical structures providing elbow stability are:

- Lateral Stabilizers: Lateral Ulnar Collateral Ligament (main)
 Radial Head (secondary)
 Epicondylar tendons and muscles (secondary)
- Anterior Stabilizers: Coronoid and anterior capsule
- Medial Stabilizers: Medial Collateral Ligament (main)
 Epitrochlear tendons and muscles (secondary)
- Posterior Stabilizers: Olecranon and posterior capsule

The elbow instability is created by the lesion of one or more of these structures: as the numbers of structures involved increases, the lesion pattern becomes more severe, with true elbow dislocations, that can represent an orthopedic emergency, in case of nerves or vessels impairment.

BIOMECHANICS OF THE LESIONS

Nowadays it's widely accepted that the fundamental model of elbow instability is triggered by a posterolateral rotational mechanism: the elbow, in fact, during a fall on the extended (or partially flexed) arm with the forearm in supination (that represent the most frequent fallen mechanism in these traumas), from the moment the hand arrives on the ground, undergoes an increasing compressive axial load with the body approaching to the ground; on this fulcrum, the body tends to undergo an internal rotation, which, at the upper limb, translates into an external rotation of the forearm, that remains in the supine position (holding the hand with the palm facing to the ground). Since the mechanical axis on which the elbow is working during this fall is positioned laterally, with respect to the articulation itself, the sum of the forces determines, at the elbow joint, a stress in valgus and in supination, which, added with axial load, is able to determine a subluxation or a true dislocation, with a posterolateral rotatory mechanism.

The first Authors to suggest this biomechanical mechanism were Osborne and Cotterill [20], which demonstrated the constant presence of the lesion of the Lateral Collateral Ligament and of the lateral elbow capsule in patients with recurrent elbow dislocation, and, at the same time, described good clinical results with the surgical repair of the lateral elbow structures, based on the biomechanical pattern of posterolateral rotatory instability, which was later better defined and brought to the fore by the clinical and the biomechanical studies conducted by the group of Mayo Clinic and in particular by O'Driscoll [21]. This type of mechanism exposes the joint structures to compressive and "cutting" forces that can create not only chondral lesions, but also fractures of intrinsic bone stabilizers, determining the pattern of complex elbow instability, which we will widely describe in the next paragraph.

BIOMECHANICS OF ELBOW INSTABILITY

Elbow instability biomechanics was precisely outlined in 1992 by O'Driscoll and Morrey, who proposed a circular pattern of progressive elbow stabilizers destruction, divided into three stages, which increase with the trauma severity [22]: once defined the posterolateral rotatory instability (PLRI), every valgus stress with supination and axial load causes to the elbow several lesions that originate in its lateral part, which is the one with the maximum stress; in stage 1 the lesion of the Lateral Ulnar Collateral Ligament (LUCL) occurs, which determines an elbow subluxation. As the trauma's energy increases, the soft tissue lesion mechanism progresses circularly: in stage 2, the breakdown of the remaining portions of the LUCL is associated with the rupture of both anterior and posterior joint capsule, creating an incomplete posterolateral elbow dislocation, that often conventional radiograms are not able to diagnose, as the coronoid remains perched on the trochlea. If the trauma energy increases, the disruption continues on the medial elbow compartment (stage 3): the posterior part of the Medial Collateral Ligament is torn, allowing the elbow to reach a lateral dislocation, by the posterolateral rotatory mechanism: the joint is completely dislocated, rotating around the anterior band of the Medial Collateral Ligament, which remains the last intact structure (stage 3A); in stage 3B also this structure is injured and the instability mechanism is complete: nothing can oppose the elbow dislocation, which can be directed posteriorly (more frequently) or anteriorly and the reduction can not be maintained.

In summary, dislocation is the ultimate event of a pathological instability mechanism of three degrees, which originates in the lateral side of the elbow, that is subjected to the greater stress during overweight in valgus, supine and axial load, and which extends to the remaining elbow joint components; the physiology of each stage correlates with the anatomical lesion framework and with the level of the related instability. Simple elbow instability can be associated with cartilage damage, vascular injury and Volkmann's syndrome or compartmental forearm syndrome, due to the extensive ischemic damage of the soft tissues. The late complications concern the ROM decrease and the formation of peri-articular ossification.

ELBOW DISLOCATION CLINICAL EXAMINATION

In the case of a patient with posterior elbow dislocation, this should be reduced in supination, to minimize the trauma on the coronoid and on the medial elbow aspect, where there may still be some not-injured soft tissues; the Mayo Clinic indications suggest to reduce the elbow under general anesthesia or at least in narcosis [21], as the need to mimic the injury mechanism and the tractions required expose the patient to an impressive painful experience; the reduction manoeuvre is a forced supination in extension, applying a force in valgus and traction on the elbow to release the coronoid; at this point, the true reduction is made in flexion and varus, while maintaining traction. Once the elbow is reduced to an anatomical position, after X-ray confirmation, it is necessary to test the degree of the residual instability, through manoeuvres that evaluate the stability in varus, in valgus and in the postero-lateral mechanism. A forced pronation position

is capable of minimizing instability degree 1, 2 and 3, as it uses the intact remaining fibers of Medial Collateral Ligament as a boulder; the stability in varus and valgus is firstly tested in full extension, then in incremental flexion degrees (greater than 30 ° in order to release the olecranon from the olecranic pit, avoiding its stabilizing effect). The posterolateral rotatory instability is tested by performing the pivot shift lateral elbow test: a supine patient with an elevated arm is evaluated bringing the elbow to a stress in valgus and supination with increasing flexion rates; in the patients able to relax or in the ones under general anesthesia, once the flexion proceeds, a palpable and audible noise appears, determined by the joint reduction. If the articulation is stable or moderately stable in flexion, a conservative treatment protocol can be undertaken, but if the joint rests unstable, even at high flexion rates, the surgical treatment with open reduction and capsular and ligament reconstruction is needed [21].

1.3.2 Complex Instability of the Elbow

The complex elbow instability is defined by Morrey, the first author to have systematized its biomechanics, as a condition that causes elbow instability due to the presence of lesions in the articular bone structures and in the capsular and ligamentous components of the elbow [23, 24].

BONY ELBOW STABILIZERS

The contribution that the two collateral ligaments can provide to an intact elbow, against the varus and valgus stress, is about 50% along the ROM [25]; The only exception is the elbow in full extension: in this case the ligament contribution is absent and the stability is determined just by the bony structures of the ulno-humeral joint (olecranon and coronoid) and by the anterior capsule. Since the contribution to the elbow stability given by soft tissues (ligaments, joint capsule) in the rotatory mechanisms has been discussed in the previous paragraph, in this one we will focus just on the elbow bone stabilizers, whose value is now well consolidated in the Literature [26].

RADIAL HEAD

As already stated above, the radial head has a role of secondary elbow stabilizer: a functional Medial Collateral Ligament, in fact, is the main opponent of a deforming force in valgus and it is widely demonstrated that, in the case of a resected radial head with an intact MCL, the elbow does not show instability [26]; after a MCL lesion, the stability against the deformations in valgus is warranted by the humeral-radial joint. In addition, the intimate correlation between the radial head and the ulnar portion of the Lateral Collateral Ligament makes the radial head a fundamental stability factor against the posterolateral rotatory instability mechanisms [27]. The radial head, even if biomechanically is a secondary elbow stabilizer, has a central role against both valgus stress and posterolateral rotatory instability (PLRI), so the anatomical osteosynthesis or the prosthetic replacement are fundamental to restore the joint stability.

OLECRANON

Olecranon is crucial in supporting the loads across the forearm, in particular in the axial direction, as demonstrated by experimental studies which have shown that the removal of more than 50% of the olecranon structure creates an irreversible elbow dislocation [28].

CORONOID

Experimental and clinical studies have shown that it is necessary to have at least 50% of the coronoid integrity with the radial head conserved, in order to maintain elbow joint stability and function: a coronoid injury with fractured or removed radial head makes the articulation severely unstable **[23]**.

CHAPTER 2:

The clinical-radiological assesment of the Essex Lopresti syndrome

An appropriate treatment of the Essex Lopresti lesion requires a complete knowledge of the forearm stability biomechanics and a clinical comprehension of this complex pattern, with the aim to obtain an early diagnosis, both in acute and in chronic lesions. When the patient presents a RH comminuted fracture, the clinician must consider the possibility to face an Essex-Lopresti lesion.

2.1 Clinical Assesment

An IOM disruption is easily missed in the patients with Essex Lopresti lesion, firstly because the clinician can't rely on the usual imaging techniques: the clinical history and the physical examination of the patients are essential to diagnose an Essex Lopresti lesion. The trauma mechanism is usually a violent axial load on the forearm; the typical patient is a male, hard worker or athlete, with a story of an high-energy fall down. The commonest symptoms in a primary or secondary forearm instability are: pain in the posterior aspect of the wrist (increased with forearm supination) and in the elbow, when the proximal part of the radius abut against the capitellum; loss of range of motion, mainly in forearm supination and in wrist extension; evidence of posterior prominence of the distal ulna at the wrist (fixed subluxation); hand grip and pronation weakness, with forearm discomfort if manipulated by the clinician; apprehension at the elbow valgus manoeuvres, because of painful instability.

The clinical evaluation starts from the elbow stability: an Essex Lopresti lesion usually shows a Lateral Ulnar Collateral Ligament tear, sometimes associated with a Medial Collateral Ligament lesion. Drawer, Pivot Shift, Valgus and Varus-Pronation Tests (also fluoroscopy assisted) are the usual manoeuvres to perform. Once evaluated the elbow, the clinician must analyze the forearm: in the acute lesions, the IOM palpation is difficult because of the pain, picture already suspect for the diagnosis; in the chronic pattern, we suggest to perform the "C-Fingers" comparative test: the arm lies on a table with the elbow flexed at 90 degrees and the forearm vertical to the floor plane; the clinician uses the thumb, in opposition to the other fingers (like a "C" letter), to squeeze the forearm space and push alternatively the dorsal and the volar side, evaluating the muscular-IOM resistance in pronation and in supination; the test must be comparative with the health side and could be invalidated by a strong muscular hypertrophy and by a significant edema. We usually check a clinical tenderness at the middle third (Central Band) and at the more distal part (Dorsal Oblique Band) of the forearm: any resistance loss of one or more forearm parts is suspect for a partial or complete IOM tear. The last clinical test to perform it's the DRUJ stability evaluation; the forearm rotation decreases because of the anatomical dislocation of the ulna, that loses its normal position in the sigmoid notch of the radius and becomes subluxed dorsally and distally; in addition, the wrist extension is blocked, because the distal ulna impinges upon the dorsal carpus. The physician tests the DRUJ with the dorsal-volar comparative translation of the ulna in neutral position, in supination and in pronation.

2.2 Imaging

We must consider that a two millimeters translation of the radius in the proximal direction usually occurs after a radial head excision, without clinical symptoms. Otherwise, a radius translation bigger than 10 mm creates considerable functional impairment.

- X-ray: a postero-anterior and lateral view of elbow and wrist are mandatory, as well as grip view of both wrists. The Grip view can be helpful in detecting dynamic radial shortening, that represents a change in ulnar variance with the active function of the forearm. To obtain a correct grip view series, it's necessary to put the wrists in pronation and the x-ray beam directed with an angle of 15 degrees centred on the DRUJ. Another X-ray of the wrists should be taken in the same pronated position, while the patient grip a dynamometer at 20 kg., if the pain allows it.
- dynamic fluoroscopic evaluation, which demonstrate the possibility of correcting forearm longitudinal instability, applying an axial traction.
- Ultrasound comparative and dynamic study: this method is quicker and less expensive than MRI and allows a dynamic evaluation of the interosseous membrane.
- MRI depicts the static anatomical status of the IOM and its tears, but the result of this exam can be invalidated by artifacts, due to the trauma effects or to previous forearm surgical procedures.

2.3 The Longitudinal-Transversal Instability Manoeuvres

- Axial stress test **[29]**: it consists of a manual traction under anesthesia, applied through the hand and the wrist; with the forearm in the supine position, the shoulder is abducted at 90° and internally rotated, the elbow is bended to 90° and the forearm is held in neutral rotation. A longitudinal traction is applied and an X-ray study is performed to the wrist and the elbow with a lateral comparative view, before and after traction: a distal radial migration of 5 mm should be considered a sign of instability.
- The “Muscular Hernia Sign” **[30]**: during a dorsal forearm ultrasound examination under anesthesia, an antero-posterior pression is applied by the physician on the anterior side of the forearm: if the interosseous ligament is torn, the volar muscles pass through the disrupted IOM, creating the typical images of a muscular hernia. The test must study the Central Band and Dorsal Oblique Band.
- Radius Pull Test **[31]**: this test has been planned using cadaver models, after the experimental excision of the RH and the following disruption of IOM and TFCC. In the clinical practice, this test is performed during the surgical treatment: a positive Pull Test provides a proximal radial migration ≥ 3 mm; the migration of 6 mm or more is observed in gross instability of the forearm with injuries of the IOM and of the Triangular fibro-cartilage complex (TFCC).
- Intraoperative Radius Joystick Test **[32]**: It's a manoeuvre to test the longitudinal and the transversal stability of the forearm during surgery; the procedure is similar to the Smith's one. The forearm is placed in maximal pronation and the arm is held firmly to immobilize the humerus. A clamp is placed on the radial neck and pulled laterally, using moderate force. The test is positive if the proximal radius moves laterally. The test is negative if the radius remains stable (positive predicting value 90%, negative pr. value 100%).

The clinical instability manoeuvres are the fundamental step in the diagnosis of an Essex Lopresti injury: this is our assessment protocol: Preoperative time: 1) Elbow stability, IOM “C-Fingers” Test; 2) fluoroscopic and ultrasound dynamic forearm evaluation (Axial stress test; Muscular Hernia Sign); 3) comparative dynamic DRUJ stress test. Intraoperative time: 4) Radius Pull Test; 5) Radius Joystick Test.

These manoeuvres are highly sensitive for the acute lesions, but they provide useful informations also in chronic patterns, bringing useful informations on the possibility to correct the forearm longitudinal and transversal instability with RH replacement, ulnar shortening osteotomies and IOM-DRUJ plasties.

CHAPTER 3:

Surgical options in the Unstable Fractures of the Forearm

Early diagnosis is mandatory because the treatment of the unstable fractures of the forearm in the early phases shows better outcomes than in the late ones. The aim of surgical treatment is to restore the triarticular forearm relationship by:

- restoring bones length
- reconstructing of the IOM Central Band
- stabilizing DRUJ and PRUJ

Proximal radial migration is approximately 5 mm in acute and 10 mm in chronic Essex-Lopresti injuries. Bone length equalization can be obtained in acute through the radial head reconstruction or substitution, checking the DRUJ reduction. In the chronic patterns we suggest always to perform an ulnar shortening and to insert a radial head prosthesis if the capitellar cartilage is healthy and when the longitudinal forearm instability has been corrected.

Multiple techniques have been described for the Central Band reconstruction: Marcotte and Osterman in 2007 defined an algorithm for the management of acute and chronic instabilities [19]; they performed an IOM reconstruction both in acute and in chronic lesions, also in presence of a radial head prosthesis. These Authors used originally a Bone-Patellar Tendon-Bone autograft for Central Band plasty in the chronic cases; this procedure is currently being performed using bone-ligament-bone allograft, eliminating, in this way, the donor-site morbidity. Several tendon grafts and synthetic devices have been described for the treatment of forearm instability. Skahen et al used Palmaris Longus or half of the Flexor Carpi Radialis tendon, but these grafts do not provide adequate strength for the Central Band reconstruction [33]. Achilles tendon allograft restores approximately 50% of the transferring forces of the native IOM, as demonstrated by Tomaino et al [34]. Sellman et al [35] and Sabo et al [36] described the use of nylon rope to perform a flexible Central Band reconstruction and found that this construct could restore the stiffness, but only when the radiocapitellar articulation had been restored. Finally, Kuzma et al [37] described the clinical use of the Pronator Teres to reconstruct the Central Band.

Our surgical practice in Faenza Orthopedic Unit, after some cases of Tibialis Posterior graft at the beginning of our experience, actually does not provide for allografts, because of the host reaction risk and of the absence of tendon synovialization, contrary to what happens in the intrarticular ligamentous reconstructions. Furthermore, the tendons require a precise measure length and larger tunnels, that can weaken the ulna, so we actually use a number 2 Ethibond nonabsorbable braid, passing 1.5 mm radio-ulnar tunnels; we can affirm, taking into consideration our and Literature data, that other devices are effective too, even if often more expensive. The fixation may be done with miniplates or titanium interference screws.

The biomechanical features of IOM plasty techniques are: the longitudinal forearm stabilization performed by the plasty (several surgical procedures allow the transverse stabilization), the isometric behaviour of the graft during the pronation and the supination, the precision in the length and in the straight resistance of the graft, the safety of the surgical procedure from neurovascular injuries and the reproducibility of the technique. DRUJ plasty is needed when the comparative dorsal-volar subluxation is evident. In chronic lesions, an arthroscopic debridement allows a better equalization between radius and ulna; several sophisticated open or arthroscopic techniques are available for DRUJ treatment but we have to consider that, in a

so challenging surgery (RH reconstruction/substitution, IOM plasty, ulnar shortening osteotomy, DRUJ plasty) an easier procedure have to be preferred, to avoid an increase in the surgical times and in the tissues exposition. In the cases of major DRUJ instability, during the Essex Lopresti repair surgery, we suggest a transient pinning, to control the exact forearm length.

Dealing with the PRUJ plasty, the Literature and our case series didn't show an absolute indication to a proximal forearm stabilization in the Essex Lopresti lesions. We used a radial loop plasty, usually with an autologous Triceps fascia, in some very unstable transverse forearm instability with ulnar or radial malunion. We agree in a precise clinical discrimination between Acute and Chronic lesions and recommend an accurate preoperative evaluation.

3.1 Acute Essex-Lopresti Syndrome (< 4 weeks).

The surgical plan, in these cases, is based on:

- Radial Head reconstruction or replacement: if the radial head fragmentation does not allow a stable synthesis, the prosthesis is the best choice: it must be placed in line with the ulnar sigmoid notch. The Kocker approach is our preferred. Unsatisfactory results of the radial head prosthesis can result from residual forearm longitudinal microinstability, with pain and risk of stem loosening. A radiological transparency around the stem is a not rare event: we noted a stable and widely movable elbow with a progressive radial neck bone reabsorption, without cases of prosthetic loosening. To contrast similar events, some Companies are introducing macroporous straight stems, that should improve intrinsic stability of the implants; the loose-fit stems remain an useful device, avoiding from the start this kind of problems.

- Elbow Ligaments reconstruction: after a correct performance of the clinicals test for elbow stability, under fluoroscopy, is frequent to find a lesion of the Lateral Ulnar Collateral Ligament and/or of the Medial Collateral Ligament: we suggest to suture both the ligaments, mainly when a RH prosthesis has to be implanted. A residual elbow instability, after a substitution, can be the cause of capitellar chondral lesions.

- IOM plasty: Marcotte and Osterman [19] didn't use their technique in the acute Essex Lopresti injuries. We prefer to apply a treatment similar to Soubeyrand's procedure: in correspondence of the maximum radial bow and in the opposite part of the inner ridge, under brilliance, a five centimetres incision is made. Crossing between flexor-extensor muscles, the Pronator Teres radial distal head is recognized; maintaining an intermediate forearm rotation, a 1.5 millimeters drill is addressed, with a 20 degrees axis, compared to the longitudinal forearm axis. The chosen device for the IOM plasty crosses dorsally the forearm bones, under the extensors compartment. We suggest to use a ligament passer, like in the knee surgery. Under X-ray control, the device is stretched, forearm movement and RH pistoning are checked and the system is finally fixed. As previously described, we use a number 2 Ethibond braided, so we fix the neo-ligament with a two-holes stainless-steel plate (hand surgery plate) with three wires tied by itself; in case of necessity, is possible to untie the knot and to retension it.

- DRUJ Plasty: if DOB Ligament is intact, surgical procedure is not mandatory. In DRUJ instability a double parallel pinning (wrist in full supination) is recommended; we suggest the pins removal after 3-4 weeks, to avoid wrist stiffness.

3.2 Notes on the Radial Head prosthesis

The Literature expresses a wide consent for the use of the radial head prostheses in cases of non-repairable fractures, which require the removal of the radial head; this is especially true when other bone lesions

(coronoid and olecranon fractures) or ligamentous lesions are associated with the fracture of the radial head within the so-called "complex elbow instability" [21, 23, 27, 38, 39].

The radial head replacement is necessary both in the Complex Elbow Instabilities and in the Unstable Fractures of the Forearm (for the latter pattern, most of all in the acute cases), because of the high risk of instability worsening with the simple radial head excision and in order to prevent the occurrence of severe forearm instability in the transverse and longitudinal planes. Over the years, a wide variety of implants have been proposed to replace the radial head [40]: the modern implants are mostly made of metal. Actually, more than ten radial head prosthesis models can be found on the market, which can be divided in three different types, depending on the design of the proximal portion: Unipolar (with cylindrical heads), Anatomical (having fixed heads with anatomic design) and Bipolar (with mobile cylindrical heads).

From the Literature data and from the common experience of the surgeons, it's nowadays impossible to define the best implant on the market: Unipolar implants with loose-fit has their advantages (no radiotransparency or resorption around the stem, good motion thanks to the loose fit) and disadvantages (overstuffing difficult to prevent, stem length just short), and the same can be said for the Anatomical prosthesis (more respect for head's anatomy, difficult implant technique, radiotransparency or resorption around the stem) and for the Bipolar (easier insertion, self-alignment of the radial head with the capitellum [41], radiotransparency or resorption around the stem, polyethylene wear).

3.3 Chronic Essex-Lopresti Syndrome (> 4 weeks).

The choice of the surgical option depends on: the reducibility from positive to neutral of the ulnar variance at the wrist (Longitudinal Instability), the time passed from the trauma and the the stability of the DRUJ (Transverse Instability).

The surgical plan is based on:

- Elbow ligamentous reconstruction: frequently the lateral compartment can be repaired, if the tissue maintains a good consistency, or reconstructed with graft, in case of poor quality of the residual tissue; usually epicondilar augmentation is performed. The Medial Collateral Legament, once torn, is difficult to repair, so it usually needs a reconstruction with graft.
- Radial Head Prosthesis: in case of previous Kaplan approach, a Posterior Radial Branch isolation with electrostimulation, to assess its validity, is suggested. The radial head implant, if needed, can be performed following the usual procedure. In the chronic patterns, the implant of a radial head prosthesis is not mandatory, even in the unstable elbows, because a well planned ulnar shortening, an IOM reconstruction and a DRUJ plasty can support the forearm tensions without a performing radial head.
- Ulnar Shortening Osteotomy (USO): in the treatment of the chronic Essex Lopresti Syndrome we suggest to always perform an ulnar shortening osteotomy, with the aim to decrease the compartments' tension. The osteotomy length is calculated on the residual ulnar variance at the wrist, after a radial head prosthesis, if necessary, or on the compressive bones length discrepancy, after an Axial Stress Test. The procedure begins from the 3rd medium of the diaphysis: firstly, the ulnar tunnel for ligamentoplasty is prepared, then the calculated bone cylinder is resected and a compression osteosynthesis with plate and screws is performed.

- IOM Plasty: in the chronic cases ligamentoplasty is clearly recommended, following the technique previously described. For the correct planning, on the surgical field, of ulnar osteotomy and IOM plasty, we suggest a temporary DRUJ pinning.

- DRUJ Plasty: as already pointed out in the preceding paragraphs, several techniques have been described, both open and arthroscopic. In Essex-Lopresti treatment, we use the Fulkerson-Watson technique, a very simple and quick procedure, which uses a tendon, autograft or homograft, passed in a loop figure around the ulnar neck **[42]**. We use one or two 2.4 mm. anchors at the ulnar surface of the radial metaphysis to fix the loop. Other techniques can be performed: Darrach, Souvee-Kapandji and Synostosis **[43]** are used operations, but they should be considered as salvage procedures.

CHAPTER 4:

Clinical experience in the Unstable Fractures of the Forearm

4.1 Definition of the study

Following the rules of Bologna University for the final project (thesis), this data analysis does not require any permission from Institutional Review Board, because of the didactic purposes of the thesis itself. This procedure has been applied taking into consideration that all the clinical data had been collected in an enabled healthcare facility (Azienda USL della Romagna).

“Tesi non notificata al Comitato Etico in quanto finalizzata all’acquisizione di competenze di natura metodologica per il raggiungimento di finalità didattiche”.

4.2 Clinical experience and results in Faenza Hospital Orthopedic Unit

I analyzed the database of Dr. Maurizio Fontana (Chief of the Orthopedic Unit of Faenza Hospital), evaluating the cases of Unstable Fractures of the Forearm: in the period between 2010 and 2016 ten patients have been treated, all male, with a mean age of 37 years; all the injuries had been caused by high energy trauma. Eight cases were chronic Essex-Lopresti injuries, two cases were acute.

The first three cases, at the beginning of the experience, were treated for an IOM reconstruction with an allograft of Posterior Tibial Tendon (frozen allograft from Rizzoli Institute Tissue bank, Bologna, Italy), but the high diameter of the radial and ulnar tunnels needed for these implants, with the consequent risk of bone lesions, drove us to look for a different plasty technique, with the aim to reduce the dimensions of the used device. Following this purpose, the remaining patients were treated with different devices: the fourth patient had an IOM plasty with an artificial ligament (LARS, Ligament Augmentation and Reconstruction System, Arc sur Tille, France), the fifth one received an Ethibond braid (Ethicon US, Sommerville, NJ, USA) and the last five were treated with a suture tape device (Ultratape, polyethylene UHMW, Smith & Nephew, London UK). The patient treated with the Ethibond braid suffered the acute rupture of the IOM plasty device and needed a revision surgery with Ultratape, with good results.

Six of the eight patients of the chronic group underwent an ulnar shortening osteotomy and one of this six received also a radial head prosthesis removal, because of the chronic capitellar impingement with a severe cartilage damage. At a mean follow up of 22 months, the mean ROM for the acute cases was 5-140 degrees in flexion-extension, 68-0-66° degrees in pronation and supination, with no wrist functional limitations; the mean ROM in the chronic cases was 24-127 degrees in extension and flexion, 54-0-47 degrees in pronation and supination, 58 degrees in wrist extension and 63 degrees in wrist flexion, without impairment in the wrist movement in the ulnar and radial direction. At the same mean follow up, the mean Mayo Clinic Elbow Performance Score were 89/100 points for the chronic cases (due to approximately 18° less in supination, maybe deriving from imperfect ligament isometry and DRUJ plasty absent), result that can be defined as good, and 97,5/100 points for two acute cases (MEPS result 100 and 95 respectively), confirming what we stated in the previous chapters, about the improvement of the functional results in the acutely treated patients. No wrist pain persistence was referred, but we pointed out three quick radial neck resorptions, that are not infrequent in the radial head prosthesis (metal monopolar and bipolar implants) with the new press-fit design, as widely stated by the recent Literature [44-45]. The MEPS is a clinical test universally used to assess the elbow function, but it is not excellent for the study of the forearm. We researched into the Literature for the existence of forearm specific clinical tests, without

results; several tests, that analyze the whole superior limb in its function, are well described, but none with a specific destination for the forearm. Based on these considerations, we proposed a new forearm score (Forearm Italian Performance Score, FIPS), that analyzes pain, joints motion, joints stability, grip strenght, radiological evidence and functional status. FIPS test is still under scientific validation from the Italian Society for Shoulder and Elbow Surgery (SICSeG) and from the Hand Surgery Italian Society (SICM), so we decided to avoid its use in this study, preferring to follow the already validated clinical tests.

4.3 Literature review

During our clinical experience of IOM reconstruction a continuous review of the Literature has been performed, with the goal of a continous maintainance of the highest scientific level in the treatment of our patients. We performed the last revision of the Literature the 20th of November 2017, using PubMed.gov, looking all the articles dealing with our subject. The research for "IOM AND reconstruction" found 29 articles: after the abstracts reading, just seven of them were inherent in the study or in the treatment of the Unstable Forearm Fractures (Essex Lopresti injuries). Two of these articles [46-47] were based on cadaveric model study, without analysis of in vivo treatment; one article [48] dealt with a revision of the biomechanic and clinical Literature, analysing the different devices to rebuilt the central band. The other four articles were clinical studies that analysed the treatment of chronic Essex Lopresti syndrome with different devices. Gaspar et al [49] in very recent work analysed ten cases of chronic Essex Lopresti lesions, dividing them into two groups, the first composed of five cases, treated with a single-bundle technique, versus other five cases (secon group), treated with a double-bundle IOM reconstruction; in all the cases the device used was a Mini-TightRope (Arthrex, Naples, Fl, USA). The results were defined as good for all the patients; the forarm rotation was significantly better in the single-bundle group, while the maintenance of ulnar variance was better in the double-bundle group, with the Authors' preference for this latter technique. Meals et al [50] performed a review of the Literature for the different reconstruction techniques and purposed a case report of IOM plasty in a chronic Essex-Lopresti injury, using a suture-button device, reporting good results at a short term follow up. The group of Gaspar and Osterman, in a previous work [51], performed a retrospective review of ten patient with chronic Essex Lopresti syndrome, treated with ulnar shortening osteotomy (USO) and IOM reconstruction with Mini TightRope device (Arthrex, Naples, Fl, USA): at a mean follow up of 34.6 months significant improvements were obtained in elbow ROM, wrist flexion-extension, QuickDASH score and ulnar variance, but three cases failed, requiring further surgical treatments (one revision of ulnar shortening osteotomy for persisitent impingement, one revsion with ulnar osteotomy device removal for the lost in forearm supination and one fixation of a radial shaft fracture after a fall). The last article of this review was written by Grassmann et al [52]: they analysed twelve patients affected by Essex Lopresti injury, confirmed by MRI, treated by DRUJ reduction and stabilization with temporary K-wires and, in addition, radial head replacement in eight cases and radial head reconstruction in two; at a mean follow up of 59 months the clinical results were defined as good, based on Mayo Modified Wrist Score, Mayo Elbow Performance Score and DASH score.

In the same date (20th of November 2017) we performed a further PubMed.gov research, using as Keywords: "Essex Lopresti AND treatment", obtaining 136 articles; 71 articles treated calcaneal diseases (were the eponym of Essex-Lopresti is widely used for the contribution of this Author in the definition of the foot pathologies). The remaining 65 articles, were evaluated by the abstracts reading: taking into consideration the aim of our study (IOM reconstruction techniques and their results), we decide to exclude: articles written in languages other than English, case reports, review articles without a clear analysis of the Essex Lopresti syndrome treatment, anatomical descriptive articles, articles dealing with imaging techniques, historical articles and the purely descriptive clinical articles. At the end of this selection, just 15

articles were chosen for the relevance of the subject, in accordance with our matter. Five of this 15 articles had been yet cited and discussed in our previous chapters and paragraphs [19, 47, 48, 51, 52] so we analysed the remaining ten, briefly discussing also the results of the work from Marcotte and Osterman [19], which had not been pointed out in the previous pages; these Authors [19] published their results of sixteen patients, all affected by chronic Essex-Lopresti lesions, at a mean F.U. of 78 months; no patients needed secondary surgery, grip strength improved from 59% to 86% of the unaffected limb, no sign of worsening was reported in terms of pain or function than before the surgery, but 15 of the 16 patients had improved wrist pain. Schnetzke et al [53] recently performed a retrospective review of thirty-one patients with Essex-Lopresti injury, analysing the differences in the early diagnosed and acutely treated patient (sixteen, treated with DRUJ pinning stabilization in supination for six weeks) and the chronic diagnosed, underlining the better results of the acute group, with not significative differences in elbow and wrist ROM in the two groups. Bigazzi et al [54] recently described their IOM reconstruction technique with a fascia lata allograft, expressing promising early results with an easy and reproducible surgical technique, that avoid donor site disease. Matson and Ruch [55] proposed their surgical technique, based on radial head prosthesis, IOM reconstruction with a Proantor teres autograft, USO and TFCC repair, but they don't refer any clinical data. Miller et al [56] described the short results of their IOM reconstruction technique with a biceps button and a tenodesis screw, aiming to biologically reconstruct and anatomically tension the central band of the interosseous membrane. Venouziou et al [57] purposed a combination of radial head replacement and Ulnar Shortening Osteotomy in seven patient, affected by chronic Essex-Lopresti lesion; at a mean follow up of 33 months, they pointed out good clinical results at the scores used (MEPS and MWS), with elbow and wrist ROM improvement. Heijink et al [58], belonging the Mayo Clinic group, described eight cases of chronic Essex-Lopresti injury (delay of the treatment of mean 3.3 years), firstly treated with monobloc radial head prosthesis, with five failures within three years; the three failures with implant aseptic loosening, underwent a cemented bipolar implant, with long-term better results: the Authors themselves define as an imperfect treatment the only radial head prosthesis in these complex cases. Adams et al [59] in 2010 purposed an IOM central band reconstruction with a bone-patellar tendon-bone system in chronic Essex-Lopresti injuries. Chloros et al [60] in 2008 purposed a complete triarticular forearm treatment technique, consisting of radial head reconstruction, leveling of the distal radio-ulnar joint, plasty of the central band of the interosseous membrane, using a pronator teres rerouting technique, and finally repair of the triangular fibrocartilage complex: these Authors defined this technique as useful, but challenging and requiring excellent surgical technique. Soubeyrand in 2006 firstly described his innovative IOM central band reconstruction technique [61]: this article is a biomechanical study on frozen cadaver, but we have included it, being the basis for our surgical technique. Finally, Ruch et al [62] in 1999 described a technique for the triarticular forearm reconstruction of Essex-Lopresti injury after radial head excision: they purposed a technique for the plasty of the central band in conjunction with the surgical repair of the DRUJ and with the radial head prosthesis, addressing all the three anatomical structures that provide longitudinal stability of the forearm.

4.4 Discussion

The relevance of the Unstable Fractures of the Forearm treatment has emerged in the Literature just in the last four years, with more and more articles treating this complex subject; till now, few scientific evidences grew up: all the Authors agree to consider acute treatment as absolutely necessary to avoid all the problems deriving from the chronic pictures, pointing out the need for an early correct diagnosis of these diseases. Several surgical techniques are now described for the treatment of these triarticular lesions, but it's impossible to find a consensus on the most valid one, because of the exiguity of the treated patients

numbers; different devices have been described as useful in the IOM reconstruction, but a true superiority can't be found.

We have compared our experience with the ones of the Literature main Authors, drawing overlapping conclusions: the key stone to achieve a viable functional recovery of the forearm is the early detection of the injury, which is based much more on the clinical assessment than on the imaging, so every clinician must suspect an Essex Lopresti syndrome in front of an high energy trauma with PRUJ lesion and pain at the forearm and at the DRUJ. The treatment of the chronic Essex Lopresti lesions is a salvage procedure, requiring a surgical technique not easy to perform in charge of PRUJ, IOM and DRUJ. During our experience we have found a valid surgical protocol of treatment, that at the moment we have applied more in the chronic cases (eight) than in the acute ones (two): first, we prepare the radius for the radial head prosthesis, leaving in situ the trial implant, second, we proceed with an ulnar shortening osteotomy, third, we insert the definitive radial head prosthesis, trying to equalize the forearm longitudinally, fourth, we perform a plasty of the DRUJ; in a single case of chronic Essex Lopresti injury with a painful radial head prosthesis, we removed this implant and we decided to avoid a new prosthesis, because of the capitellar cartilage suffering. In the acute cases, the radial head can be repaired, if possible, or replaced, in case of complex fractures; LUCL and MCL must be tested clinically and radiologically under anesthesia and eventually surgically explored, because every lesion of the elbow stabilizers should be, in our hands, repaired; we perform IOM plasty as exposed in the previous chapters and finally, in case of DRUJ instability, we perform a pinning in full supination for 3/4 weeks. This treatment protocol gave us good results in the chronic cases and excellent results in the two acute cases; our results and the confirmations we have obtained from the Literature in the last years drive us to proceed in the application of our studies to the patients.

The Biases of this study are clear: the low number of the patients that we had treated, the lack of division between the acute and the chronic cases, the differences in the used devices during our experience and the absence of specific and validated clinical tests for the results definition of the clinic forearm treatments.

4.5 Conclusions

The fracture-dislocations of the Forearm must be classified as "Unstable Fractures of the Forearm", because they damage the functional Units of the Forearm: Monteggia, Galeazzi, Criss-Cross Injury and Essex-Lopresti lesions must be included in this group, because the intra-extrarticular fractures of one or both the forearm bones are associated with instability of almost two of the three constraints. Correct clinical evaluation and early surgery are critical for the success of the treatment of this lesions; late treatments are often related to poor outcomes.

The Essex Lopresti lesion represents the worse pattern of the Unstable Fractures of the Forearm, because of the three constraints disruption, so it can be defined as the most challenging forearm lesion for the surgeon: radial head reconstruction/substitution and DRUJ stabilization are well known and spread procedures. The IOM plasty is a well planned technique and many Authors agree on its use both in acute and chronic conditions, but the results, in the Literature, are still exiguous and not homogeneous. Furthermore the progression of partial IOM tears is still unknown, like the existence of forearm microinstability that creates condral erosion of the capitellum and stem loosening in the radial head prostheses.

Our encouraging data induce us to continue on the undertaken road, with the aim of validating the current surgical technique and, if possible, of improving it increasingly, so to provide those patients, who still could not find an hope of care in these severe injuries, an opportunity for functional recovery of the forearm, defeating the pain and the dysfunctions that the complex forearm injuries have always represented.

REFERENCES

- 1 Curr JF, Coe WA. Dislocation of the inferior radio-ulnar joint. *Br J Surg* 1946; 34: 74-77
- 2 Brockman EP. Two cases of disability at the wrist following excision of the head of the radius. *Proc R Soc Med* 1931; 24: 904-905
- 3 Essex Lopresti P. Fractures of the radial head with distal radio-ulnar dislocation: report of two cases. *JBJS Br* 1951; 33B (2): 244-247
- 4 Schemitsch EH, Richards R. The effect of malunion on functional outcome after plate fixation of fractures of both bones of the forearm in adults. *J Bone Joint Surg Am* 1992;74:1068-1078
- 5 Stewart RL. Forearm Fractures in "Surgical Treatment of Orthopaedic Trauma" JP Stannard, AH Schmidt, PJ Kregor Ed. 2007 Thieme Stuttgart
- 6 Celli A, Marongiu MC, Fontana M, Celli L. The Fracture-Dislocation of the Forearm (Monteggia and Essex-Lopresti Lesions) in "Treatment of Elbow Lesions" A Celli, L Celli, BF Morrey Ed. 2008 Springer-Verlag Italia
- 7 Moritomo H, Noda K, Goto A, Murase T, Yoshikawa H, Sugamoto K. Interosseous membrane of the forearm: length change of ligaments during forearm rotation. *J Hand Surg Am* 2009 Apr;34(4):685-91
- 8 Pfaeffle HJ, Tomaino MM, Grewald R, Xu J, Boardman ND, Woo SL, Herdon JH. Tensile properties of the interosseous membrane of the human forearm. *J Orthop Res* 1996; 14(5): 842-845
- 9 Chandler JW, Stabile KJ, Pfaeffle HJ, Li ZM, Woo SL, Tomaino MM. Anatomic parameters for planning of interosseous ligament reconstruction using computer-assisted techniques. *J Hand Surg (Am)* 2003; 28 (1): 111-116
- 10 Sage FP. Medullary fixation of fractures of the forearm: a study of medullary canal of the radius and report of fifty fractures of the radius treated with a present triangular nail. *JBJS Am* 1959;41:1489-1516
- 11 Schemitsch EH, Richard RR. The effect of malunion on functional outcome after plate fixation of fractures of both bones of the forearm in adults. *JBJSAm* 1992;74:1068-1078
- 12 Soubeyrand M, Lafont C, De George R, Dumontier C. Pathologie traumatique de la membrane interosseuse de l'avantbras *Chir de la Main* 2007, 26 : 255-277
- 13 Shepard MF, Markolf KL, Dunbar AM. The effects of partial and total interosseous membrane transection on load sharing in the cadaver forearm. *J Orthop Res* 2001; 19(4): 587-92
- 14 Hotchkiss RN, An KN, Sowa DT, Basta S, Weiland AJ. An anatomic and mechanical study of the interosseous membrane of the forearm: pathomechanics of proximal migration of the radius. *J Hand Surg(Am)* 1989; 14 (2 Pt 1): 256-61

- 15 Van Riet RP, Morrey BF. Delayed valgus instability and proximal migration of the radius after radial head prosthesis failure. *J Shoulder Elbow Surg* 2010 19: e7-e10
- 16 Jungbluth P, Frangen TM, Muhr G, Kalicke T. A primarily overlooked and incorrectly treated Essex-Lopresti injury: what can this lead to?. *Arch Orthop Trauma Surg* 2008; 128: 89-95
- 17 Pfaeffle HJ, Stabile KJ, Li ZM, Tomaino MM. Reconstruction of interosseous ligament unload metallic radial head arthroplasty and the distal ulna in cadavers. *J Hand Surg (Am)* 2006;31(2):269-278
- 18 Duckworth AD, Wickramasinghe NR, Clement ND, Court-Brown CM, McQueen MM. Radial head replacement for acute complex fracture: what are the risks factor for revision or removal?. *Clin Orthop Rel Res* 2014 Jul; 42(7):2136-2143
- 19 Marcotte AL, Osterman AL. Longitudinal radioulnar dissociation: identification and treatment of acute and chronic injuries. *Hand Clinic* 2007;23:196-208
- 20 Osborne G, Cotterill P. Recurrent dislocation of the elbow. *J Bone Joint Surg*, 1966; 48B:340
- 21 O'Driscoll SW. Elbow Dislocations. In: Morrey BF, Sanchez-Sotelo J. *The elbow and its disorders*. 4th ed. Philadelphia: Saunders Elsevier. 2009;P. 436-48
- 22 O'Driscoll SW, Morrey BF, Korinek S, An KN. Elbow subluxation and dislocation: A spectrum of instability. *Clin Orthop Relat Res*, 1992; 280:186
- 23 Morrey BF, O'Driscoll SW. Complex Instability of the Elbow. In: Morrey BF, Sanchez-Sotelo J. *The elbow and its disorders*. 4th ed. Philadelphia: Saunders Elsevier. 2009;P. 450-62
- 24 Morrey BF. Complex instability of the elbow. *J Bone Joint Surg*, 1997; 79A:460
- 25 Morrey BF. Fractures of the radial head. In Morrey BF (ed). *The elbow and its disorders*, 2nd edition. Philadelphia, WB Saunders, 1993, p. 383
- 26 Morrey BF, An KN. Stability of the elbow: Osseous constraints. *J Shoulder Elbow Surg*, 2005; 14(1 suppl S):174S
- 27 Dunning CE, Zazour Z, Patterson SD, Johnson JA, King GJW. Ligamentous stabilizers against posterolateral rotator instability of the elbow. *J Bone Joint Surg*, 2001; 83:1823-8
- 28 An KN, Morrey BF, Chao EYS. The effect of partial removal of proximal ulna on elbow constraint. *Clin Orthop Relat Res*, 1986; 209:270
- 29 Davidson PA, Moseley JB, Tullos HS. Radial head fracture. A potentially complex injury. *Clin Orthop* 1993;297:224-230
- 30 Soubeyrand M, Lafont C, Oberlin C, France W, Maulat I, Degeorges R. The "muscular hernia sign": an original ultrasonographic sign to detect lesion of the forearm's interosseous membrane. *Surg Radiol Anat* 2006; 28 (3): 372-8
- 31 Smith AM, Urbanosky LR, Castle LA, Rushing JT, Ruch DS. Predictor of longitudinal forearm instability. *JBJS Am* 2002; 84: 1970-1976

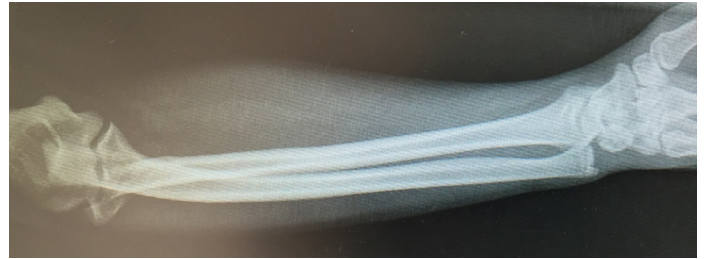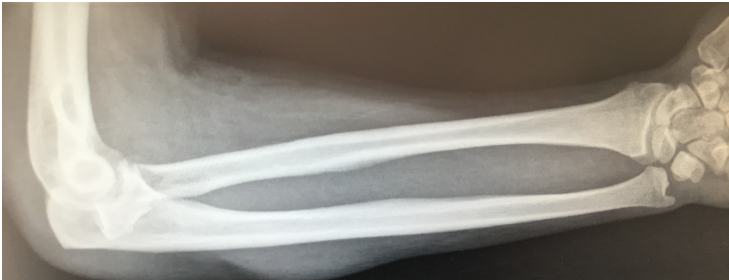- 32 Soubeyrand M, Ciais G, Wassermann V, Kalouche I, Biau D, Dumontier C, Gagey O. The intra-operative radius joystick test to diagnose complete disruption of the interosseous membrane. *JBJS Br* 2011; 93-B, 10: 1389-1394
- 33 Skahen JR 3rd, Palmer AK, Werner FW et al. Reconstruction of the interosseous membrane of the forearm in cadavers. *J Hand Surg (Am)* 1997; 22(6): 986-994
- 34 Tomaino MM, Pfaeffle J, Stabile K et al. Reconstruction of the interosseous ligament of the forearm reduces load on the radial head in cadavers. *J Hand Surg Br* 2003; 28(3): 267-270
- 35 Sellman DC, Seitz WH, Postak PD, et al. Reconstructive strategies for radioulnar dissociation: a biomechanical study. *J Orthop Trauma* 1995; 9 (6): 516-522
- 36 Sabo MT, Watts AC. Reconstructing the interosseous membrane: a technique using synthetic graft and endobuttons. *Tch Hand Up Extrem Surg* 2012Dec;16(4):187-193
- 37 Kuzma G. Reconstruction of the Essex Lopresti Injury. 2003; AAHS 33rd annual meeting. Kauai, Hi, January 8-11
- 38 Morrey BF. Radial head fracture. In: Morrey BF, editor. *The elbow and its disorders*. 3rd ed. Philadelphia: WB Saunders; 2000. p. 341-64
- 39 Beingessner DM, Dunning CE, Stacpoole RA, Johnson JA, King GJ. The effect of coronoid fractures on elbow kinematics and stability. *Clin Biomech (Bristol, Avon)*. 2007 Feb;22(2):183-90. Epub 2006 Nov 13
- 40 Zunkiewicz MR, Clemente JS, Miller MC, Baratz ME, Wysocki RW, Cohen MS. Radial head replacement with a bipolar system: a minimum 2-year follow-up. *J Shoulder Elbow Surg*. 2012 Jan;21(1):98-104
- 41 Yian E, Steens W, Lingenfelter E, Schneeberger AG. Malpositioning of radial head prostheses: an in vitro study. *J Shoulder Elbow Surg*. 2008 Jul-Aug;17(4):663-70
- 42 Purisha H, Sezer I, Kabakas F, Tuncer S, Erturer E, Yazar M. Ligament reconstruction using the Fulkerson-Watson method to treat chronic isolated distal radioulnar joint instability: short term result. *Acta Ortop Traumat Turcica* 2011;45(3):168-174
- 43 Allende C, Allende B. Posttraumatic one-bone forearm reconstruction: a report of seven cases. *JBJS* 2004;86A:364-369
- 44 O'Driscoll SW, Herald JA. Forearm pain associated with loose radial head prostheses. *J Shoulder Elbow Surg*. 2012 Jan;21(1):92-7. doi: 10.1016/j.jse.2011.05.008. Epub 2011 Aug 19.
- 45 Rotini R, Marinelli A, Guerra E, Bettelli G, Cavaciocchi M. Radial head replacement with unipolar and bipolar SBI system: a clinical and radiographic analysis after a 2-year mean follow-up. *Musculoskelet Surg*. 2012 May;96 Suppl 1:S69-79. doi: 10.1007/s12306-012-0198-z. Epub 2012 Apr 18
- 46 Werner FW, LeVasseur MR, Harley BJ, Anderson A. Role of the Interosseous Membrane in Preventing Distal Radioulnar Gapping. *J Wrist Surg*. 2017 May;6(2):97-101. doi: 10.1055/s-0036-1584545. Epub 2016 Jun 20
- 47 Drake ML, Farber GL, White KL, Parks BG, Segalman KA. Restoration of longitudinal forearm stability using a suture button construct. *J Hand Surg Am*. 2010 Dec;35(12):1981-5. doi:10.1016/j.jhsa.2010.09.009

- 48 Matthias R, Wright TW. Interosseous Membrane of the Forearm. *J Wrist Surg.* 2016 Aug;5(3):188-93. doi: 10.1055/s-0036-1584326. Epub 2016 Jun 13
- 49 Gaspar MP, Kearns KA, Culp RW, Osterman AL, Kane PM. Single- versus double-bundle suture button reconstruction of the forearm interosseous membrane for the chronic Essex-Lopresti lesion. *Eur J Orthop Surg Traumatol.* 2017 Oct 6. doi: 10.1007/s00590-017-2051-4. [Epub ahead of print]
- 50 Meals CG, Forthman CL, Segalman KA. Suture-Button Reconstruction of the Interosseous Membrane. *J Wrist Surg.* 2016 Aug;5(3):179-83. doi: 10.1055/s-0036-1584547. Epub 2016 Jun 20
- 51 Gaspar MP, Kane PM, Pflug EM, Jacoby SM, Osterman AL, Culp RW. Interosseous membrane reconstruction with a suture-button construct for treatment of chronic forearm instability. *J Shoulder Elbow Surg.* 2016 Sep;25(9):1491-500. doi: 10.1016/j.jse.2016.04.018. Epub 2016 Jun 30
- 52 Grassmann JP, Hakimi M, Gehrman SV, Betsch M, Kröpil P, Wild M, Windolf J, Jungbluth P. The treatment of the acute Essex-Lopresti injury. *Bone Joint J.* 2014 Oct;96-B(10):1385-91. doi: 10.1302/0301-620X.96B10.33334
- 53 Schnetzke M, Porschke F, Hoppe K, Studier-Fischer S, Gruetzner PA, Guehring T. Outcome of Early and Late Diagnosed Essex-Lopresti Injury. *J Bone Joint Surg Am.* 2017 Jun 21;99(12):1043-1050. doi: 10.2106/JBJS.16.01203
- 54 Bigazzi P, Marengi L, Biondi M, Zucchini M, Ceruso M. Surgical Treatment of Chronic Essex-Lopresti Lesion: Interosseous Membrane Reconstruction and Radial Head Prosthesis. *Tech Hand Up Extrem Surg.* 2017 Mar;21(1):2-7. doi: 10.1097/BTH.000000000000143.
- 55 Matson AP, Ruch DS. Management of the Essex-Lopresti Injury. *J Wrist Surg.* 2016 Aug;5(3):172-8. doi: 10.1055/s-0036-1584544. Epub 2016 Jun 20
- 56 Miller AJ, Naik TU, Seigerman DA, Ilyas AM. Anatomic Interosseus Membrane Reconstruction Utilizing the Biceps Button and Screw Tenodesis for Essex-Lopresti Injuries. *Tech Hand Up Extrem Surg.* 2016 Mar;20(1):6-13. doi: 10.1097/BTH.000000000000107
- 57 Venouziou AI, Papatheodorou LK, Weiser RW, Sotereanos DG. Chronic Essex-Lopresti injuries: an alternative treatment method. *J Shoulder Elbow Surg.* 2014 Jun;23(6):861-6. doi: 10.1016/j.jse.2014.01.043. Epub 2014 Apr 22
- 58 Heijink A, Morrey BF, van Riet RP, O'Driscoll SW, Cooney WP 3rd. Delayed treatment of elbow pain and dysfunction following Essex-Lopresti injury with metallic radial head replacement: a case series. *J Shoulder Elbow Surg.* 2010 Sep;19(6):929-36. doi: 10.1016/j.jse.2010.03.007. Epub 2010 Jun 17
- 59 Adams JE, Culp RW, Osterman AL. Interosseous membrane reconstruction for the Essex-Lopresti injury. *J Hand Surg Am.* 2010 Jan;35(1):129-36. doi: 10.1016/j.jhsa.2009.10.007
- 60 Chloros GD, Wiesler ER, Stabile KJ, Papadonikolakis A, Ruch DS, Kuzma GR. Reconstruction of essex-lopresti injury of the forearm: technical note. *J Hand Surg Am.* 2008 Jan;33(1):124-30. doi: 10.1016/j.jhsa.2007.09.008
- 61 Soubeyrand M, Oberlin C, Dumontier C, Belkheyar Z, Lafont C, Degeorges R. Ligamentoplasty of the forearm interosseous membrane using the semitendinosus tendon: anatomical study and surgical

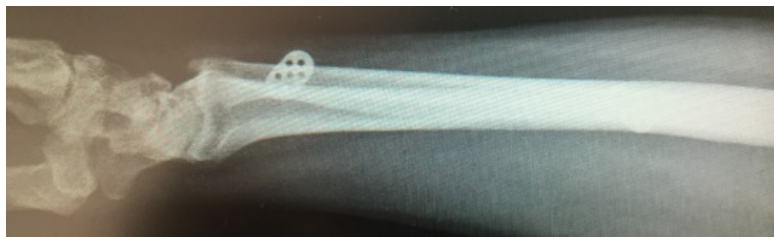
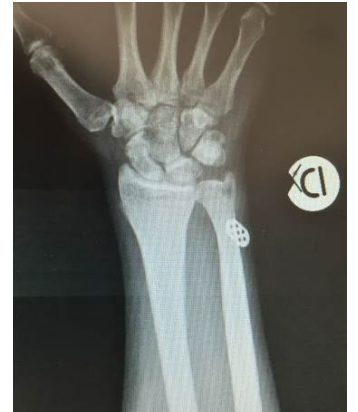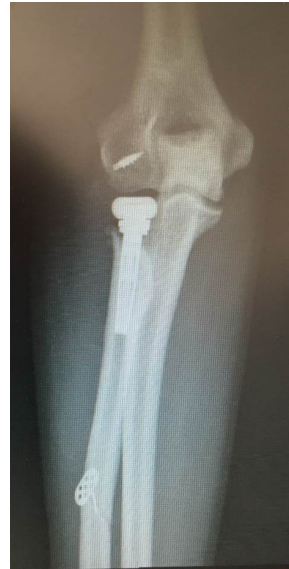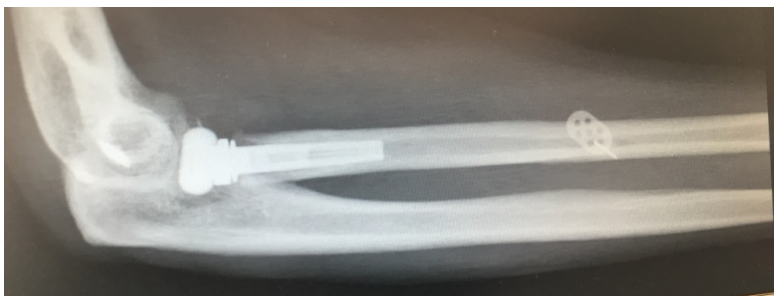procedure. *Surg Radiol Anat.* 2006 Jun;28(3):300-7. Epub 2006 Feb 11

62 Ruch DS, Chang DS, Koman LA. Reconstruction of longitudinal stability of the forearm after disruption of interosseous ligament and radial head excision (Essex-Lopresti lesion). *J South Orthop Assoc.* 1999 Spring;8(1):47-52

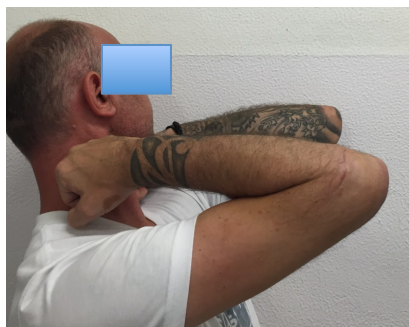Image 1: clinical case of a chronic Essex Lopresti syndrome
Male, 42 y.o., right-handed, car accident, right forearm involved



X-rays 6 weeks after the trauma



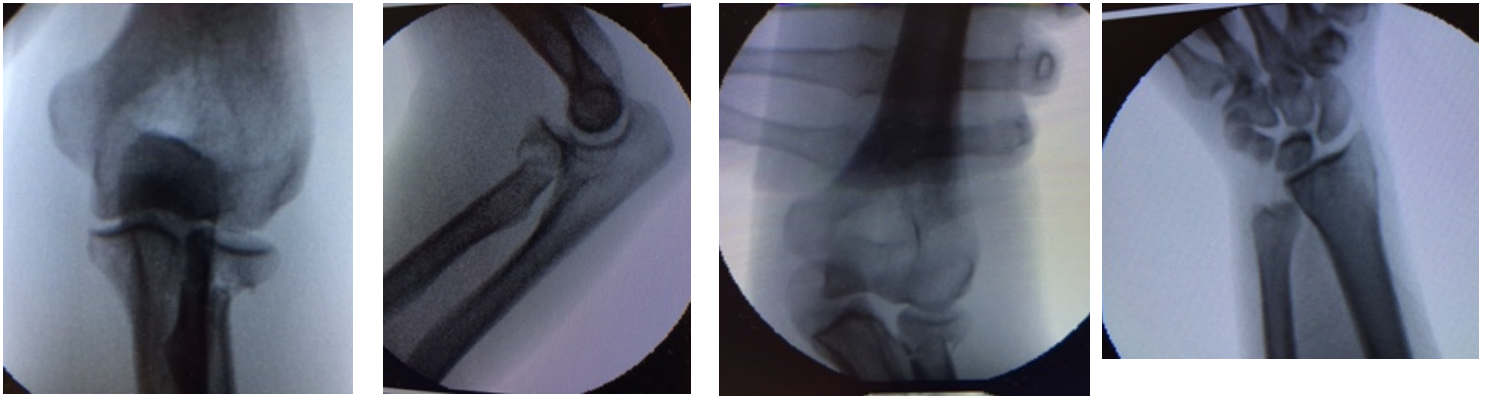
X-rays 6 months after the surgery



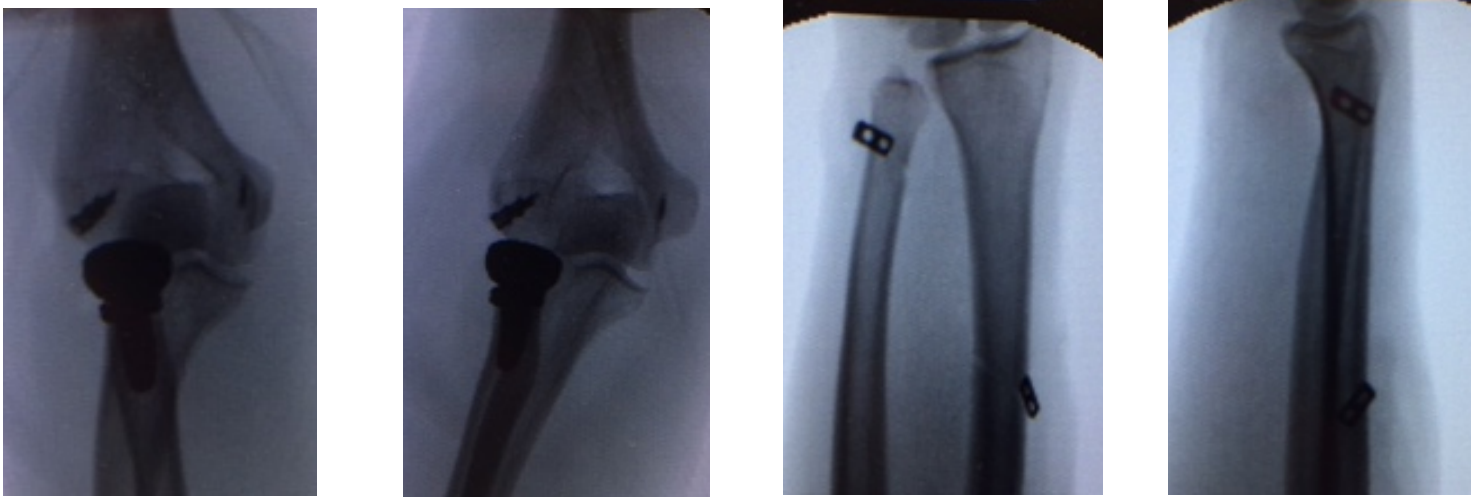
Clinical result 6 months after the surgery, MEPS 85/100



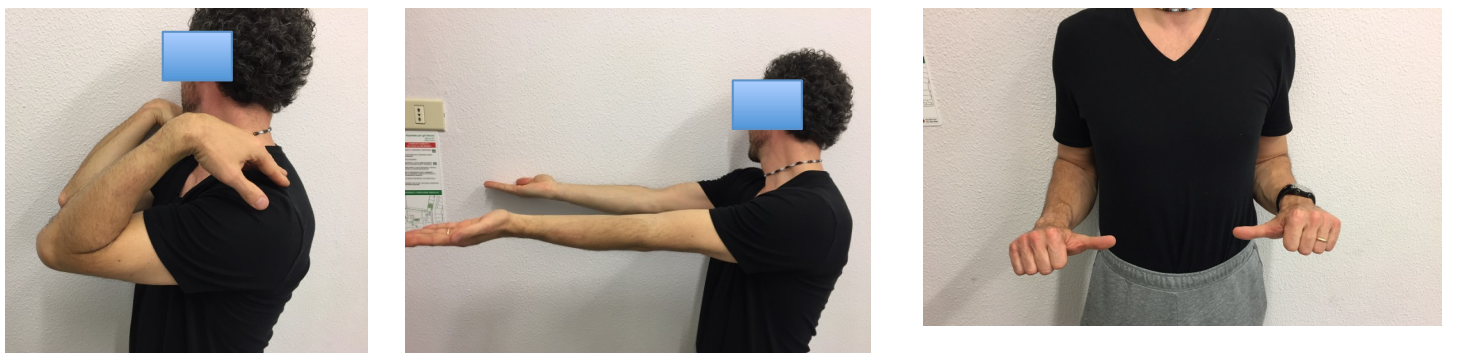Image 2: clinical case of an acute Essex Lopresti syndrome
Male, 43 y.o., left-handed, bike accident, left forearm involved



X-rays in E.R. 90 minutes after the trauma: PRUJ, IOM and DRUJ lesions are evident



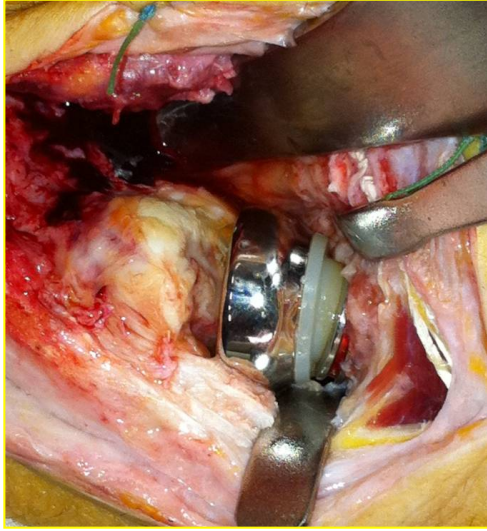
X-rays after the surgery



Clinical result 6 months after the surgery, MEPS 95/100

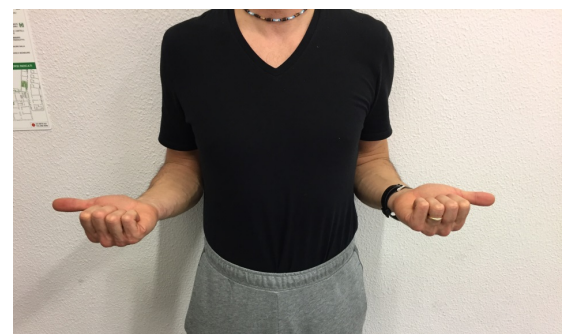

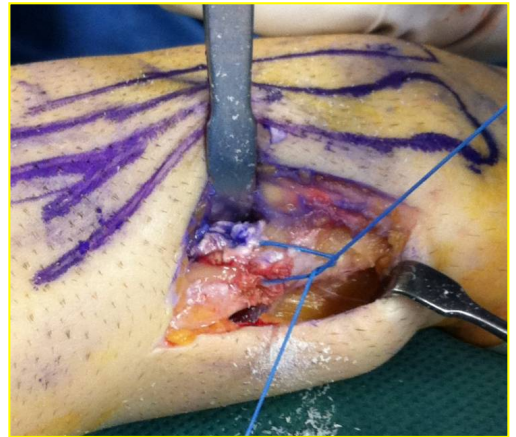
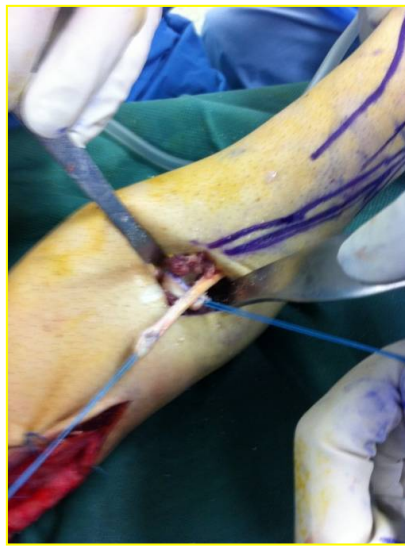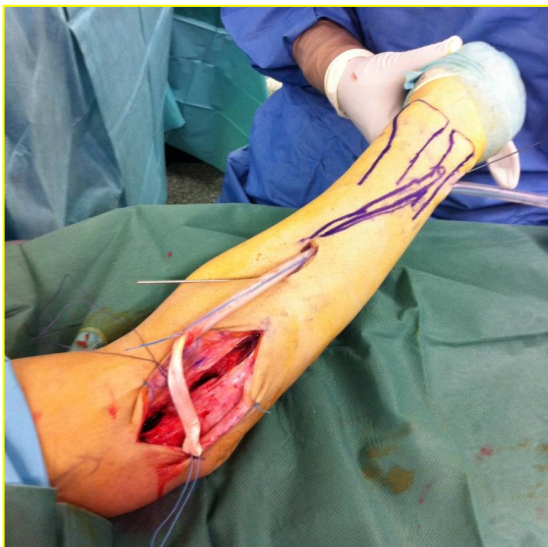Image 3: Painful radial head removal and IOM reconstruction in a chronic case of Essex Lopresti syndrome



On the surgical field, the radial head prosthesis had lost its press-fit with the radial bone and had created a severe chondral damage on the chondral surface of the capitellum, so it was removed and not replaced



IOM plasty with a Posterior Tibial Tendon (allograft)



SERVIZIO SANITARIO REGIONALE
EMILIA-ROMAGNA
Azienda Unità Sanitaria Locale di Ravenna

Presidio Ospedaliero di Faenza

Dipartimento Delle Chirurgie Specialistiche
U.O. Ortopedia e Traumatologia

Al Direttore Dipartimento Osteoarticolare ASL Romagna
Dr. Gabriele Zanotti

Faenza, 20 novembre 2017

OGGETTO: tesi Dottorato di Ricerca in Scienze Chirurgiche (Università degli Studi di Bologna) del Dr. Michele Cavaciocchi – XXX ciclo

Con la presente dichiarazione,

si attesta che

la tesi di dottorato in oggetto, dal titolo "**Unstable fractures of the forearm: a project to improve clinical comprehension and to valuate the results of the Interosseous Membrane Reconstruction**" si configura come Tesi Applicativa con preminente finalità didattica, e pertanto risulta esentata da pareri autorizzativi del Comitato Etico.

I dati dei pazienti in oggetto, trattati presso una struttura sanitaria dell'Azienda USL della Romagna (Ospedale per gli Infermi di Faenza), sono stati forniti dal Direttore dell'Unità Operativa di Ortopedia e Traumatologia (Dr. Maurizio Fontana) in forma aggregata e comunque trattati, in tutto l'iter di studio, seguendo i necessari principi di riservatezza e rispettando i principi etici della ricerca scientifica.

Il candidato
Dr. Michele Cavaciocchi

Il Direttore dell'U.O. di Ortopedia e Traumatologia, Osp. Faenza
Dr. Maurizio Fontana

Il Direttore del Dipartimento Osteoarticolare della ASL Romagna
Dr. Gabriele Zanotti

Dottorato di Ricerca in Scienze Chirurgiche - UNIBO

Michele Cavaciocchi

PROJECT TITLE:

Elbow Instability: a project to improve clinical comprehension, to validate a new classification and to evaluate the results of the early and delayed surgery

RELAZIONE TRIENNALE

During this first year a big effort was produced to find a consensus over a biomechanical and clinical comprehensive classification of simple and complex elbow instability, that in the Literature had never been defined in a complete way, with the collaboration of the main Italian experts of the elbow diseases: a new classification was defined, finding a validation from one of the main worldwide opinion leader for elbow diseases, Prof. Shawn O'Driscoll (Mayo Clinic, Rochester, MN).

Unfortunately, during the second year, some difficulties arose in the clinical validation of the biomechanical and clinical comprehensive classification of simple and complex elbow instability, previously defined, and a practical obstacle emerged: the different Italian Authors, that had defined the Elbow Instability Classification, did not find an agreement on the retrospective and prospective study to perform, with insuperable difficulties in the aggregation of the several casuistries in a single case series.

At this point, I decided to exploit the opportunities I found in my new job place (I passed from the Shoulder and Elbow Unit of Rizzoli Institute to the Orthopedic Unit of Faenza Hospital, directed by Dr. Maurizio Fontana), where an unique and innovative experience were in course: the validation of a new surgical technique, the Interosseous Membrane Reconstruction, for the complex fracture-instability of the forearm, technique based on the forerunner experience of Prof. Marc Soubeyrand from Paris, taking also into consideration the strict correlation between elbow and forearm instability.

In the last year, I have deepened the complex Fracture-Instability of the forearm and its treatment (Interosseous Membrane Reconstruction) by the biomechanical and the surgical point of view. Our case series (10 patients) is increasing and the clinical results are really encouraging from the points of view of pain relief and elbow, forearm and wrist function.

I found an important check of the interest for this subject during the Congress, held in Milan at Istituto Pini on the last month of May, on the Ligamentous Forearm Lesion: the two oral presentations I performed, dealing with diagnosis and treatment of the complex fracture-instability of the forearm, found a great interest both in orthopedic and hand surgeon, and the surgical technique, that we are using for the treatment of these complex diseases, has been widely debated and approved. These positive answers confirmed the theoretical and practical basis of this surgery.

I performed a retrospective study of the small but important case series of unstable fractures of the forearm, surgically treated at the Faenza Hospital (10 cases) following the technique described by Marc Soubeyrand, that firstly described the Interosseous Membrane reconstruction in these complex cases. This retrospective study takes into the right consideration also the biomechanical aspect of this disease.

The results of this surgical technique are encouraging, and, once arrived at a minimum follow up of 24 months for all the first ten patient, we will try to publish them in an Impacted Journal, based on the absolute rarity of our case series for the Literature and the good clinical results, considering also the

biomechanical evidences on the corrective surgery for the unstable fractures of the forearm, that, at the moment, have been rarely and just partially described.

PROJECT TITLE, FINALLY PURPOSED:

Taking into consideration the evolution of the project, I would like to propose a title adjustment:

Complex fractures of the forearm: a project to improve clinical comprehension and to evaluate the results of the Interosseous Membrane Reconstruction

Dottorato di Ricerca in Scienze Chirurgiche - UNIBO

Michele Cavaciocchi

PUBLICATIONS (Impact Factor or Index Medicus) during the PhD:

- Pogliacomi F., Aliani D., Cavaciocchi M., Corradi M., Ceccarelli F., Rotini R. Total elbow arthroplasty in distal humeral nonunion: clinical and radiographic evaluation after a minimum follow-up of three years. *J Shoulder Elbow Surg.* 2015 Dec;24, 1998-2007 doi: 10.1016/j.jse.2015.08.010
- Rotini R, Cavaciocchi M, Fabbri D, Bettelli G, Catani F, Campochiaro G, Fontana M, Colozza A, De Biase CF, Ziveri G, Zapparoli C, Stacca F, Lupo R, Rapisarda S, Guerra E. Proximal humeral fracture fixation: multicenter study with carbon fiber peek plate. *Musculoskelet Surg.* 2015 Sep;99 Suppl 1:1-8. doi: 10.1007/s12306-015-0371-2. Epub 2015 May 12.
- Rotini R, Bettelli G, Cavaciocchi M, Savarino L. Pseudotumor due to metallosis after total elbow arthroplasty. *Indian J Orthop.* 2017 Jan-Feb;51(1):103-106. doi: 10.4103/0019-5413.197557.

BOOK CHAPTERS:

- Guerra E, Fabbri D, Bettelli G, Marinelli A, Cavaciocchi M, Rotini R. ORIF in Three-/four-Part Fractures. In *Simple and Complex Fractures of the Humerus. A Guide to Assessment and Treatment*; editors Castoldi F, Blonna D, Assom M. Springer Ed 2015. P 75-89. ISBN: 978-88-470-5306-9.
- Marinelli A, Guerra E, Bettelli G, Cavaciocchi M, Rotini R. Surgical Approaches Based on Fracture Patterns. In *Simple and Complex Fractures of the Humerus. A Guide to Assessment and Treatment*; editors Castoldi F, Blonna D, Assom M. Springer Ed 2015. DOI 10.1007/978-88-470-5307-6_24
- Rotini R, Cavaciocchi M, Bettelli G, Zaccarelli L. Elbow Prosthesis in Distal Humeral Fractures In *Simple and Complex Fractures of the Humerus. A Guide to Assessment and Treatment*; editors Castoldi F, Blonna D, Assom M. Springer Ed 2015. DOI 10.1007/978-88-470-5307-6_26
- . Rotini R, Cavaciocchi M, Krishna K, Guerra E. Olecranon elbow pain in sportsmen. In Pederzini L, Eygendaal D (eds.). *Elbow and Sport*. Springer, pag 85-99. ISBN 978-3-662-48742-6
- Rotini R, Cavaciocchi M, Bettelli G, Marinelli A. Capitellar and Trochlear fractures of the distal humerus. In Pederzini L, Eygendaal D (eds.). *Elbow and Sport*. Springer, pag 251-59. ISBN 978-3-662-48742-6