

Alma Mater Studiorum – Università di Bologna

**DOTTORATO DI RICERCA IN
SCIENZE BIOMEDICHE**

Ciclo XXIX

Settore Concorsuale di afferenza: 05/H1

Settore Scientifico disciplinare: BIO/16

**EFFICACY AND SECURITY OF BLEB NEEDLING REVISION IN FAILED
TRABECULECTOMIES OF GLAUCOMA PATIENTS: A 10-YEAR RETROSPECTIVE
STUDY (2004-2014).**

Presentata da: Dott. Corrado Gizzi

Coordinatore Dottorato

Prof. Lucio Cocco

Relatore

Prof. Lucio Cocco

Esame finale anno 2017

TABLE OF CONTENTS

1. PART ONE

1.1 INTRODUCTION	pag.1
1.2 EPIDEMIOLOGY OF GLAUCOMA	pag.3
1.3 TRABECULECTOMY AND THE FIGHT AGAINST SCAR FORMATION	pag.4
1.4 WOUND HEALING	pag.5
1.5 TRIGGERS FOR FIBROSIS FOLLOWING TRABECULECTOMY	pag.6
1.6 WOUND HEALING MODULATION: PRESENT AND FUTURE	pag.8
1.7 RISK FOR FAILURE AND THE ROLE OF ANTIMETABOLITES	pag.9
1.8 5-FLUOROURACIL (5-FU)	pag.11
1.9 BLEB NEEDLE REVISION TYPE: BLEB MORPHOLOGY AND THE LOCATION OF RESISTANCE	pag.12
1.10 BLEB NEEDLE REVISION (BNR): WHEN TO CONSIDER IT AND WHEN TO AVOID IT	pag.13
1.11 BLEB NEEDLE REVISION (BNR): TECHNIQUES	pag.14
1.12 BLEB NEEDLE REVISION (BNR): COMPLICATIONS	pag.16

2. PART TWO

2.1 STUDY INTRODUCTION	pag.17
2.2 PATIENTS AND METHODS	pag.17
2.3 STATISTICAL ANALYSIS	pag.20
2.4 RESULTS	pag.20
2.5 DISCUSSION	pag.29
2.6 REFERENCES	pag.34

INTRODUCTION

Glaucoma is a chronic optic neuropathy with a characteristic pattern of loss of optic nerve fibres and field of vision which can lead to visual impairment or even blindness in the most aggressive cases. Many subtypes of the disease are recognized, however primary open angle glaucoma (POAG) is the most common form worldwide. Yet POAG etiology is only partially understood and there is still uncertainty on the mechanism through which optic nerve fibres die. Intraocular pressure (IOP) is the only modifiable risk factor and therefore the treatment of the disease focuses on its reduction by means of medications, laser treatments or surgeries.

When it comes to surgery trabeculectomy is still the gold standard. This procedure was first described by Cairns¹ in 1968 and then was subjected to many revisions to improve its safety and efficacy profile.²

The suboptimal function or complete lack of drainage of a trabeculectomy bleb challenge the ophthalmologist to choose the most appropriate option in order to restore the adequate IOP control. In the early post-trabeculectomy phase the cause of an increased IOP is usually a blockage at the level of the ostium (tissue, blood or vitreous), an excessive tightening of the scleral flap sutures or an increased resistance at the level of the conjunctiva due to a Tenon's cyst formation or a scarred down bleb for a primary failure. On the other hand, in the late postoperative phase, even after years of successful drainage function, a trabeculectomy site may fail for an unfavorable deposition of fibrous tissue beneath the scleral flap or at the interface between the episclera and the conjunctival/Tenon's capsule, compromising thus the filtration. This can happen both following a specific "trigger" for the extracellular matrix deposition, like an intervening cataract surgery, and also independently for nonspecific reasons.

When the reason for a trabeculectomy failure is deemed to be an excess of fibrous tissue preventing the activity of the fistula, one has to opt for either a conservative management or a more aggressive interventional approach. In the decision making process many variables need to be born in mind: the mechanism of glaucoma, the technique employed for the original surgery, the state of the conjunctiva, the eventual comorbidities, the time to failure from the original surgery and the patient's preference are some of them.

The conservative management usually relies on the use of topical aqueous suppressants, such as carbonic anhydrase inhibitors, alpha-2 agonists and beta-blockers. However, in cases where the trabeculectomy is still at least partially functioning, some may argue that the reduction of flow might further deflate the bleb and promote its definite scarring down. In the early postoperative phase topical steroids have a widely accepted role in preventing excessive bleb scarring. However their effect on the trabeculectomy site at a later stage is

more controversial and the lack of a strong evidence on the matter, leave space for multiple views. While for some topical steroids are unlikely to affect the drainage, others are firm believers of a steroid response due to modifications on the trabecular meshwork or on the bleb remodeling.

Conversely, the interventional approach can be minimal, via the use of topical injections of antimetabolites (5-FU and MMC) and more recently anti-VEGF (bevacizumab), or more aggressive, with the revision of the trabeculectomy, a redo procedure or a glaucoma drainage device implantation. Furthermore when the choice falls on a revision the options are either to rescue the bleb with a needling procedure or to perform a more invasive full revision of the original site, which involves the opening of the conjunctiva and the dissection of the tissues.

The bleb needling revision (BNR) is performed entering the conjunctiva far back from the filtering site and puncturing and cutting the fibrous tissue around the bleb with sweeping motion in the attempt of increasing the outflow. Traditionally three types of BNR are recognized: type 1 when is limited to the subconjunctival space, type 2 when the needle is used to break fibrous tissue under the scleral flap (often blindly identified by the consistence of the tissue encountered) and type 3 when the anterior chamber is fully entered. The procedure is often associated with the use of antimetabolites to enhance the chances of success. Most of the times 0.1 ml of the pyrimidine analogue 5-fluorouracil (5-FU) is injected under the conjunctive surrounding the treatment area. However other techniques implement the antibiotic mitomycin C (MMC) usually applied prior to the procedure either on top of the conjunctiva via sponges or under the conjunctiva by means of the injection of a small amount of a low concentration of it.

The main advantages of the BNR are that is a quick, repeatable procedure that requires a limited manipulation of the tissues. On the other hands there are some risks such as: bleeding (under the conjunctiva or in the anterior chamber), conjunctival buttonholes and leakage, hypotony, shallowing of the anterior chamber, corneal decompensation, damage to intraocular tissues, aqueous misdirection (malignant glaucoma), choroidal detachment and infection.

The opinion on the efficacy of the BNR is still debated: some believe that should be avoided in the first place, as it jeopardizes the remaining function of the bleb and doesn't offer any real advantage to the patient and the glaucoma specialist; others strongly advocate its use early on, even when the trabeculectomy activity seems adequate but the morphology of the bleb appears suboptimal. Moreover, when it comes to counsel a patient, the outcome of the procedure is difficult to predict and based on the results of previous studies and clinical experience, the chance of success is considered to be roughly 50 percent.

The aim of this study is to cast some light on the safety and efficacy of bleb needling revision performed on partly or completely failed trabeculectomies. In order to minimise the variables that could affect the reliability of the results we opted to include only the procedures carried out during a time window of 10 years (2004-2014) in the same setting (Moorfields Eye Hospital, NHS Trust, London, UK) with a consistent technique.

EPIDEMIOLOGY OF GLAUCOMA

Glaucoma is considered the main cause of irreversible blindness worldwide. A recent epidemiological meta-analysis was conducted in order to estimate the prevalence of glaucoma in 2013 and to project the number of people affected by 2020 and 2040.³ This was done using the World Population Prospects of the United Nations, which project the world population number based on population consensus and demographic surveys taking into account mortality and fertility rates. The pooled worldwide prevalence of glaucoma in the study was 3.54% with 95% credible intervals (CrIs) of 2.09-5.82%. Africa showed the highest prevalence of POAG with 4.20% (2.08-7.35) whereas Asia had the highest prevalence of primary angle closure glaucoma (PACG) with 1.26% (0.34-3.30). Europe showed the lowest global prevalence (2.93% [1.85-4.40]) among the macro-geographic continental regions considered (Asia, Africa, Europe, north America, Latin America and the Caribbean, and Oceania). In terms of subtypes of glaucoma the prevalence of POAG was estimated at 2.51% (1.54-3.89) and the prevalence of PACG at 0.42% (0.13-0.98). Translated in to numbers it means that 6.77 million people were estimated to have glaucoma (both POAG and PACG) in Europe in 2013, with a prevalence of POAG 6 times higher than PACG.

Furthermore the projections carried out showed a worldwide increase of prevalence from 64 million people in 2013 to 76 million in 2020 and 111 million in 2040. This striking rise in the numbers is largely explained by the increase of life expectancy primarily in Asia and Africa with a consequent larger base of people at risk for glaucoma. From a European perspective, the number of people affected by glaucoma were estimated to be 7.12 million by 2020 (5.67 with POAG and 1.46 with PACG respectively) and 7.85 by 2040 (6.39 with POAG and 1.46 with PACG respectively)

The results of the Bayesian multiple-adjusted meta-regression analysis are noteworthy. In fact they showed an higher odds ratio for POAG in men (OR: 1.36), people living in Africa (OR: 1.97), people living in urban areas (OR:

1.58) and people of African ancestry (OR: 2.80). The OR was 1.73 for each decade of age in the age interval 40-80. Interestingly the age effect was found to be more pronounced in people of European and Hispanic ancestry compared to others.

Among the epidemiological studies on glaucoma conducted in Italy, three of them seem of particular interest. The Egna-Neumarkt Study⁴ investigated the prevalence of ocular hypertension (OHT) and glaucoma in a population aged 40 or older in Alto Adige. The participation rate to the study was higher than 70% and the investigators found a 2.1% prevalence of OHT and a 1.4%, 0.6% and 0.6% prevalence of POAG, PACG and normal tension glaucomas (NTG) respectively.

The Casteldaccia Eye Study⁵ found a 1.2% prevalence of chronic open angle glaucoma (presumably inclusive of POAG and NTG) and a 4.3% prevalence of OHT. The study was conducted in a small Sicilian town among people aged 40 or more and had a participation rate close to 70%.

The Ponza Ophthalmological Survey⁶ included an analysis of prevalence of glaucoma among the population residing in Ponza Island. The survey achieved a participation rate higher than 80% and enrolled people aged 40 or older. The results of the survey showed a 2.51% prevalence of POAG, a 0.97% prevalence of PACG and a 6.00% prevalence of OHT, with higher figures compared to the afore mentioned studies in terms of POAG and OHT.

TRABECULECTOMY AND THE FIGHT AGAINST SCAR FORMATION

When the glaucomatous optic neuropathy (GON) progresses despite the use of all the eyedrops that proved to be effective and tolerated by the patient (i.e. maximal tolerated medical treatment or MTMT) the next sensible options is the surgery in the majority of the cases. Trabeculectomy remains the most common option as a first surgical treatment for most of the glaucoma subtypes. The rationale of the procedure is to create a bypass through the scleral wall to allow the egress of aqueous humor in the extraocular space under the conjunctiva, where a small blister, commonly termed “bleb”, is formed. From that area the aqueous humor is reabsorbed by the blood and lymphatic vessels of the conjunctiva. Alternatively microscopic droplets of aqueous can work their way through the conjunctiva and join the tear film where they are drained by the lacrimal pathways. These tiny droplets are sometimes visible in forms of microcysts at the level of the filtering site during the clinical examination at the slit lamp; their presence is thought to be a sign of a functioning trabeculectomy.

Regardless of the extra care taken during surgery to fashion the filtering site, the human body is programmed to heal the wounds, and trabeculectomy makes no exception. The wound healing process is the major responsible for the impediment to achieve higher success rates. Known risk factors for scar formation are previous surgeries involving the conjunctiva, long use of preserved eyedrops, conjunctival inflammation (such as in belpharoconjunctivitis, commonly seen in elderly), ethnicity (with greater risk in people of African ancestry) and young age. Therefore one of the most challenging part of the management of the surgical patients is the fight against scar formation which can impede the success of the procedure. It has been reported that despite the refinements of the surgical technique and the use of antiinflammatory drugs and antimetabolites, still 35-43% of the patients don't achieve a complete success, that is the maintenance of the target pressure without glaucoma drops.⁷⁻⁹ In the following paragraphs the main sources of failure of the trabeculectomy are briefly discussed.

WOUND HEALING

The wound repair response takes place in order to maintain the structural integrity of the tissues. On the other hand modulation of wound healing is deemed crucial in order to preserve the function of the filtering site. The healing process can be divided in three stages: the inflammatory phase, the proliferative phase and the remodeling phase.

In the inflammatory phase the macrophages, recruited by means of increased tissue level of transforming growth factor beta (TGF- β), play a pivotal role creating the appropriate supply of cytokines (such as platelet derived growth factor [PDGF], fibroblast growth factor [FGF], epidermal growth factor [EGF] and TGF- β) and interacting with fibroblasts and T lymphocytes to coordinate tissue response.¹⁰

Also T lymphocytes are considered essential to regulate the transition between the different stages of the healing response.

In the proliferative phase the first event is the restoration of the epithelial integrity by means of migration of the surrounding cells and then by cell multiplication. Subsequently the granulation tissue forms, thank to two concomitant events: angiogenesis and fibroplasia.

Angiogenesis, promoted by the release of vascular endothelial growth factor (VEGF) and bFGF by platelets and macrophages, leads to the formation of new capillary beds through proliferation of vascular endothelial cells.¹¹

Fibroplasia, on the other hand, is induced by increased levels of PDGF and TGF- β and consists in the proliferation of fibroblasts and the deposition of connective tissue in the site of injury.¹² The fibroblasts migrate in the tissue through an appropriate balance between matrix metalloproteinases (MMPs) and tissue inhibitor metalloproteinases (TIMPs). The deposition of collagen is stimulated by the presence of TGF- β and interleukin-4 (IL-4).¹³

Tissue remodeling is the last phase of wound healing. It involves the transition to a different type of tissue through the differentiation of some of the fibroblasts in myofibroblasts and in fibrocytes and the change of the prevailing type of collagen (from type III to type I). The transition from fibroblast to the highly contractile phenotype typical of myofibroblast is promoted by TGF- β and is marked by the expression of alpha smooth-muscle actin (α -SMA) and by increasing levels of extracellular matrix (ECM) proteins such as fibronectin, tenascins and collagens.¹⁴ In the fine balance between an excessive amount of scarring and the lack of appropriate wound repair, it seems that myofibroblast apoptosis plays a vital role. In fact, in a simplistic manner, scar formation may be considered as an overreaching wound healing process, characterized by a prolonged or enhanced myofibroblast stimulation.

TRIGGERS FOR FIBROSIS FOLLOWING TRABECULECTOMY

The conjunctiva may respond to a variety of stimuli modulating the healing process. A careful clinical examination and assessment of the past ocular history can highlight potential risk factors for an abnormal scar formation. The vast majority of the patients undergo a surgical treatment for glaucoma following many years of uninterrupted medical treatment. A good proportion of them may also show a certain degree of ocular surface disease (OSD) which may be exacerbated by the chronic exposure to some toxic preservatives and allergenic glaucoma drugs.¹⁵ Chronic inflammation leads to increased levels of IL-1 and TNF- α which promote fibrosis via a TGF- β mediated pathway.¹⁶⁻¹⁷ Also Th2 lymphocytes mediated allergic reactions, such as those caused by certain IOP lowering agents, may enhance fibrosis via an IL-13 mechanism.¹⁸ Previous studies have

demonstrated a beneficial effect of pretreatment with short courses of non-steroidal or steroidal anti-inflammatory drugs prior to trabeculectomy.^{19,20}

The conjunctiva may also be in an activated state following previous accidental traumas or surgical manipulations. As far as the inflammation is concerned the same principles hold true; however in these cases also the composition of the ECM play an important role. The ECM changes its phenotype and retains a certain amount of growth factors like VEGF-A, FGF and TGF- β which may be released and readily available following a surgical injury.²¹ Furthermore certain molecules, such as the ED-A splice variation of fibronectin,²² and some matricellular proteins, such as CTGF and SPARC, may act as enhancers of the scar formation.^{23,24}

Aqueous humor may have a detrimental role in the filtering function of the trabeculectomy. Some of the molecules contained in the aqueous of glaucoma patients, such as TGF- β , VEGF, PDGF, IL-8, serum amyloid A, TNF- α and plasminogen activated inhibitor (PAI-1) , exhibit a profibrotic activity.²⁵⁻²⁸ Along these lines lower levels of VEGF-A and TGF- β have been associated with more favorable outcomes of glaucoma surgery.²⁵

Together with the biochemical effect of the aqueous composition also the physical properties of the aqueous outflow may impact on the tissue response to the surgery. The characteristics of the flow (in terms of speed and direction), hydrostatic pressure, tissue permeability and absorption have been investigated and found to contribute to the scar formation process.²⁹ Interestingly the sole interstitial flow of aqueous in the subconjunctival space is deemed to activate biochemical signals for fibrosis via mechanotransduction.³⁰

In an in vitro 3D cell culture model, slow interstitial fluid flow has proven sufficient to induce fibroblasts proliferation, TGF- β 1-dependent myofibroblast transdifferentiation and ECM rearrangements.³¹ Furthermore experiments with cells in a 3D environment showed that ECM fibers orientation was perpendicular to the direction of the fluid flow in order to reduce the mechanical stress on the cells.³² This resulted in a lower permeability and higher hydrostatic pressure. All these observations need to be born in mind and further investigated in order to reach a better insight on their effect on the surgical outcome.

WOUND HEALING MODULATION: PRESENT AND FUTURE

The inflammation preceding and following glaucoma surgery is typically targeted by the use of topical steroid drugs. In order to limit the scar formation the filtering site is treated intraoperatively with application of the antimetabolite mytomicin-C (MMC) at variable concentration depending on the risk profile.³³ The drug is an antibiotic derived from an actinobacterium, *Streptomyces caespitosus*, and acts via a non-cell cycle-specific manner. It alkylates and cross-links DNA in target cells and therefore inhibits DNA synthesis with a cytostatic effect leading to cell apoptosis in Tenon's fibroblast cell cultures. One common treatment protocol entails the application of 0.4 mg/ml MMC soaked sponges for 3 minutes intraoperatively on a broad area of episcleral tissue and under the scleral flap to prevent fibrosis and promote a posterior flow of the aqueous. Another common antimetabolite is 5-fluorouracil (5-FU) which is typically administered postoperatively via subconjunctival injection of 0.1-0.2 cc of 50 mg/ml solutions.³⁴ The drug, which is commonly used also following trabeculectomy bleb needle revisions (BNR), is less potent compared to MMC as it targets DNA only in cells on S-phase.

Despite the good results obtained with the state of the art treatment, an increasing amount of studies are exploring alternative solutions to achieve more consistent results.

The inhibition of cyclin-dependent kinase (CDK) has shown preliminary good results in rabbit models of glaucoma surgery and seems to offer a viable approach to inhibit excessive fibrosis with a better safety profile compared to antimetabolites.³⁵

Previous phase III clinical trials, exploring the use of an isoform-specific TGF- β 2 antibody, have failed to prove an important role of TGF- β 2 inhibition in limiting fibrosis.⁷ That was unexpected considering the role of the molecule in the promotion of scarring and its increased concentration in the aqueous of glaucoma patients. However it is possible that a different scheme of administration or the use of an antibody targeting both isoforms of TGF- β may yield different results. Yet a safety issue may arise, as TGF- β is implicated in immunomodulatory and tumor-suppressive activities.

The employment of anti-VEGF for glaucoma surgery is receiving increasing attention in the recent years. Although the use anti-VEGF alone is not superior to current antimetabolites, it seems that its combination with the actual treatment strategies permit to achieve better results.³⁶ VEGF is responsible for increased vascular permeability and oedema, hence its inhibition lessen the availability of pro inflammatory and pro fibrotic molecules at the level of the filtering site.

Rho-kinase inhibitors are likely to enter the market of glaucoma eyedrops in the near future. However they may exhibit another interesting effect in reducing the cell contractility and therefore downregulate mechanotransduction.³⁷ Statins inhibit Rho signaling by preventing its post-translational isoprenylation and showed similar effects on myofibroblast transdifferentiation as Rho-kinase inhibitors in vitro.³⁸

MicroRNAs (miRNAs) are non-coding RNA segments that are regulating protein expression patterns on a broad scale. There is mounting evidence linking decreased concentration of miR-29 to higher degree of fibrosis.³⁹ On the other hand overexpression of miR-29 suppressed collagen-1 expression in human Tenon's fibroblasts.⁴⁰ These observations pave the way for a potential role of miR-29 as an antiscarring agent in glaucoma surgery.

RISK FOR FAILURE AND THE ROLE OF ANTIMETABOLITES

The remodeling process of the filtering site following trabeculectomy doesn't subside few months after surgery indeed it can continue for as long as 1 year before slowing down and reaching a quiescent phase. In order to achieve the desired wound modulation there are 4 critical points to consider. First the surgery must be performed with the least possible manipulation and trauma of the tissues, so that the inflammation response is minimized. Second, whenever possible, the conjunctiva should be spared from pro-inflammatory agents, such as benzalkonium chloride preserved drops and ideally treated with topical steroid to diminish the load of inflammatory cells. Third an antimetabolite augmented procedure, which consists in the use of agents such as MMC and 5-FU, should be employed, with a concentration and application time proportional to the predicted risk of failure. Lastly a trabeculectomy bleb needle revision, enhanced by the use of MMC or 5-FU, should be considered when, despite all the efforts, the bleb shows signs of imminent failure.

Success rates of trabeculectomies may vary depending on many factors, among which are patient demographic characteristic, technique employed, use of antimetabolites, follow-up time and success criteria. In an elderly, low risk population, MMC-augmented trabeculectomy achieved an IOP <18 mmHg in 73.1% of the eyes and IOP < 14 mmHg in 56.7% of the eyes at 9 years.⁴¹ More recently a retrospective study highlighted the satisfactory results obtained in 428 eyes of 395 patients who underwent trabeculectomy. Of these, 63% were performed with MMC, 30% with 5-FU and the rest without antimetabolites. At 2 year follow-up 87% of the eyes were achieved overall success according to the first criterion (IOP \leq 21 mmHg and 20% IOP reduction from baseline)

and 86% were considered successful based on the second criterion (IOP \leq 18 mmHg and 20% IOP reduction from baseline).² Interestingly about 17% of the eyes required a 5-FU-augmented bleb needling revision; this underscores the important role of this procedure in the armamentarium of the glaucoma surgeon.

5-FU is a pyrimidine analogue which prevents inclusion of thymidine in the DNA chains and interferes with RNA and ribosomal RNA synthesis. As a result it can effectively control the scar deposition and improve the outcome of trabeculectomy. Even though it has been used as an intraoperative antimetabolite, at present its use is largely prevalent in the postoperative time, for the treatment of failing bleb via subconjunctival injections. Another major role of 5-FU is in the antimetabolite-enhanced bleb needle revision procedures at the dose of 5-10 mg/ml. Studies investigating the efficacy of 5-FU as the sole wound-healing modulator found improved outcomes compared to trabeculectomy without the use of antimetabolites. The success rates reported range from 77.8% at 5 years for low risk eyes (success criterion: IOP \leq 21 mmHg),⁴² to 49% for high risk eyes.⁴³ Interestingly, in studies where 5-FU-augmented trabeculectomies were compared head to head with those enhanced with MMC, the results were mostly non statistically different.

It is widely accepted that some eyes have a less satisfactory outcome following trabeculectomy. Typical risk factors for anterior filtering surgery failure are: young age (less than 40 years old, although no clear cutoff has been established), black ethnicity, previous long exposure to preserved eyedrops, previous surgeries involving the conjunctiva, and certain secondary glaucomas (such as traumatic, neovascular, uveitic and ICE related). The mechanisms proposed to explain the higher failure rate in these eyes are different: they range from an increased number of conjunctival fibroblasts and inflammatory cells (macrophages, lymphocytes and mast-cells) to changes in the aqueous humor composition due to a blood aqueous barrier breakdown or an anatomical insult. These changes result in a primed conjunctiva which is more likely to exhibit an exaggerated healing response and therefore a lower chance to achieve the desired outcome.⁴⁴ For this reason is extremely important to modulate the intraoperative and postoperative approach (particularly in terms of the use of antimetabolites) in order to prevent a potential early failure.

5-FLUOROURACIL (5-FU)

5-Fluorouracil (5-FU) is a pyrimidine analogue with a chemical structure similar to thymine and uracil. It was first synthesized and described in 1957 by Dushinski et al⁴⁵ and it was later found to have promising effect in the treatment of different types of tumors (head, neck, gastrointestinal tract and breast). 5-FU has several cytotoxic properties that make it useful in Ophthalmology: 1) its active metabolite, 5-fluorodeoxyuridine 5'-monophosphate (FdUMP), inhibits thymidylate synthetase and the incorporation of thymidine in DNA (only in cells in S phase of the cell cycle); 2) it is incorporated in RNA and it interferes with the synthesis of RNA and ribosomal RNA; 3) it causes indirect disruption of the actin cytoskeleton in a dose-dependent way; 4) it promotes apoptosis of Tenon's capsule fibroblasts.⁴⁶

The potential benefits offered by 5-FU have prompted its employment in different areas of ophthalmic surgery, ranging from glaucoma filtering surgery to pterygium, lacrimal surgery, proliferative vitreoretinopathy and ocular surface neoplasia. As far as glaucoma surgery is concerned, 5-FU has been investigated in primary trabeculectomy, combined cataract and glaucoma surgery, trabeculectomy bleb needling revision, pediatric glaucoma surgery and glaucoma drainage device implantation. In primary trabeculectomy studies have shown improved surgical outcomes both with repeated 5-FU subconjunctival injections postoperatively,⁴⁷ and with 5-FU soaked sponges application during the intraoperative time. Interestingly the outcomes of 5-FU augmented trabeculectomy were reported to be similar of those of MMC enhanced trabeculectomy.^{48,49} However the latter has replaced intraoperative 5-FU in the vast majorities of the cases, owing to a cell-cycle independent cytotoxic effect and the evidence of inhibiting effect on vascular endothelial cells highlighted in an animal experimental model.⁵⁰ Trabeculectomy bleb needling revision is a procedure to revive failing or failed trabeculectomies; in these settings 5-FU is still the most common drug employed to improve the outcomes due to its favorable efficacy and safety profiles. The antifibrotic drug is typically administered at the end of the surgery via subconjunctival injections next to the area of the filtering bleb.

In terms of complications, 5-FU is considered more forgiving than more potent antimetabolites such as MMC. However there are still concerns related to its effect on actively replicating cells such as corneal epithelial cells. Relatively common manifestations of corneal exposure to 5-FU include punctate keratopathy, filamentary keratopathy, and epithelial defects. These changes are usually reversible and self-limiting. However more serious events like bacterial ulceration, corneal melting and perforation have also been described. In order to limit the corneal exposure to 5-FU, a no-reflux injection technique is commonly adopted which consists in the use of cotton-tip applicator to tamponade the reflux of 5-FU from the needle entry site.⁵¹

Another potential source of complications is the thinner and more avascular anatomy of the bleb achieved with the use of an antifibrotic agent. This can lead to bleb oozing, bleb or wound leaking and bleb related infections such as blebitis and bleb related endophthalmitis. Despite the fact that there is no way to have complete control on the amount of effect of antifibrotic agents on the ocular tissues, one interesting technique has been described to highlight tissue exposure to 5-FU or MMC. This technique is based on the use of trypan blue dyed 5-FU and MMC and has the advantage to easily demarcate the extent of the treated area and to pinpoint potential issues such as antimetabolite entry in the AC and reflux from the needle entry site. According to the authors of the study, the modified procedure showed that there is a direct correlation between the advancement of the needle under the conjunctiva and the tissue surface reached by the injected antimetabolite. Moreover the presence of subconjunctival fibrotic bands is delineated by the distribution of the dye, allowing for a more extensive breakage of scar tissue. This approach, provided its efficacy is demonstrated to be equal to the standard one, might help to minimize the rate of complications related to the use of antimetabolites.⁵²

BLEB NEEDLE REVISION TYPE: BLEB MORPHOLOGY AND THE LOCATION OF RESISTANCE

Prior to undertake a bleb needle trabeculectomy revision, one must carefully assess the eye to be operated on in order to establish the best surgical approach. Once an obstruction of the ostium has been excluded via gonioscopy, other features of the bleb can be examined. In the attempt to facilitate the description of the bleb morphology several authors have developed grading systems, of which the most wide spread are the Indiana Bleb Appearance Grading Scale (IBAGS) and the Moorfields Bleb Grading System (MBGS).⁵³ They both provide handy tools to classify the bleb morphology, although sometimes a bleb can present with a mixed morphology which make it difficult to allocate it to a specific subtype.

Depending on the site where the fibrosis process occurs, the location of resistance may vary and may therefore affect the morphology of the bleb. When the scar tissue surrounds the filtering bleb a so-called “ring of steel” forms and confers an “encapsulated” or “encysted” appearance to the bleb. This translates in a dome-shaped, tense, elevated bleb which is translucent and filled by the trapped aqueous. In other circumstances the main site of resistance may be at the level of the scleral flap and the bleb is usually shallow or completely flat. A classification of needling has been proposed to indicate where the procedure takes place: type I needling is

performed over the sclera at the level of Tenon's or subconjunctival tissue (this is primarily useful in the management of encapsulated blebs); type II needling extends the sweeping motion of the needle tip to the edge of the scleral flap in order to release a fibrotic seal around it; finally type III needling advances under the scleral flap and through the sclerostomy in the anterior chamber and reforms the whole outflow pathway.⁵⁴ It is straightforward that the latter type is more likely to cause early hypotony for the complete absence of resistance which may follow its execution.

It has to be born in mind that just as one's ability to assess the function of a trabeculectomy by the bleb morphology is limited, so is the ability to determine the location of outflow resistance by the sole clinical inspection of the bleb (with the notable exception of Tenon's cysts).

BLEB NEEDLE REVISION (BNR): WHEN TO CONSIDER IT AND WHEN TO AVOID IT

The main and most common reason to offer a bleb needling revision to a patient is undoubtedly the presence of a failing or failed trabeculectomy bleb. When it comes to classify a bleb as "amenable" to needling there is still no strict consensus among different glaucoma specialists. Some textbooks and peer-reviewed papers consider bleb needling revision a surgical approach applicable only when dealing with encapsulated blebs (also known as Tenon's cysts). These typically form in the early period after trabeculectomy or phacoemulsification (in eyes which previously underwent trabeculectomy) due to the deposition of scar tissue around the filtering area resulting in a dome-shaped, elevated, vascularized and tense bleb. Others have described the outcome of this procedure on blebs with a great variety of morphologies, ranging from dome-shaped encapsulated blebs to flat and scarred blebs.

However there are other instances when bleb needling revision could prove useful. For example, in the presence of a bleb with a markedly elevated profile which is associated with bleb dysesthesia, the revision may help to achieve a more diffuse, flatter morphology with a resulting improvement in the ocular comfort and possibly the resolution of the symptoms.

Also thin-walled, avascular, cystic blebs may be considered as appropriate targets for bleb needling revision. It has been shown that these types of blebs are associated with an increased risk of bleb related infections (BRI), such as blebitis and bleb-related endophthalmitis (BRE).⁵⁵ While the former is confined to the external ocular

tissues and can have satisfactory outcomes when promptly recognized and treated, the latter involves the intraocular space and can lead to devastating consequences to the structural and functional integrity of the eye .

Bleb needling revision relies on the breakage of scar tissue via sweeping movements of a fine needle tip; in the traditional technique there are no flow restrictors and the success of the procedure depends on a fine balance between the removal of resistance and the presence of residual fibrotic tissue to prevent a crash of the IOP. Therefore there are circumstances where a bleb needling revision might be contraindicated for the increased risks of persistent hypotony and hypotony-related complications (i.e. flat anterior chamber, choroidal detachment, suprachoroidal hemorrhage, hypotony maculopathy and pseudo-papilloedema ex-vacuo). Patients with a potentially impaired ciliary body function, such as those with a history of chronic uveitis and diabetes mellitus or those who underwent previous ciliary body ablation procedures, present with a higher risk of these complications. The same holds true in patients who are traditionally at greater risk of hypotony following trabeculectomy, such as high myopes. In those cases different approaches, such as a same site extensive trabeculectomy revision, a redo trabeculectomy or a glaucoma drainage device insertion.

BLEB NEEDLE REVISION (BNR): TECHNIQUES

The procedure can be performed at the slit-lamp or in a more controlled environment such as the operating theatre. The preparation of the eye is similar to other surgeries, with the use of a drape to isolate the eye, a lid speculum to maintain the proper exposure of the tissues, and povidone iodine 5% eyedrops as disinfectant.

In terms of antifibrotic agents the choice is between mitomycin-C (MMC) or 5-fluorouracil (5-FU). A small amount of the former (0.1 ml) can be injected under the conjunctiva immediately before the procedure in a concentration which may vary from 0.2 mg/ml to 0.5mg/ml, depending on the risk factors for recurrence of failure. Alternatively MMC can be applied on top of the conjunctiva pre or post-operatively via soaked sponges for a variable period of time (generally no longer than 6 minutes). However 5-FU is still the most common antifibrotic agent employed after needling, partly because is less potent and therefore considered safer to inject. Also there are concerns related the overdose of MMC to which ocular tissues are exposed, with potential long term side effects such as scleral thinning and ciliary body shutdown. For these reasons some

clinicians are reluctant to “poison” the eye with repeated exposure to MMC. 5-FU is injected next to the bleb area, rather than into the bleb, in a concentration usually between 5 to 10 mg (0.1 to 0.2 ml of 50mg/ml formulation).

The sharp instrument used to puncture and break the fibrotic septa which separate the loculations within the bleb may also vary depending of the type of bleb and on the preference of the operator. A 30 gauge fine needle has the advantage of producing a tiny self-sealing conjunctival entry site but is less effective when trying to disassemble thick fibrotic bands. On the other hand a 23 gauge microvitreo-retinal (MVR) blade ensures a greater cutting ability but requires a proper closure of the entry hole with a suture or diathermy. An intermediate solution is the use of a 25 gauge (orange) needle, which has some of the advantages of both the aforementioned instruments. The entry site should be at least 10 mm from the main loculation of the bleb which sit above the scleral flap. Ideally the bleb margins should be approached either from the temporal or the superior side, to promote the extension of the filtering area in those directions. The nasal side should be avoided if possible, since an overdraining bleb on that side has higher chances to cause dysesthesia.

One of the main limitations of BNR is the lack of a fine control over the amount of flow restored. The aim of the procedure is essentially to defy the outflow resistance which, depending on the bleb morphology, may be predominantly at the level of the scleral flap or at the level of the subconjunctival space. The needle employed for the procedure allows to reduce the risks of a significant bleb leakage and doesn't require to place a suture at the end of the maneuver. On the other hand there is no direct exposure of the subconjunctival tissues and every step is performed either looking carefully through the conjunctiva or, when the visibility is suboptimal or completely absent, relying only on the tactile feedback of the tissues. This can lead to an insufficient disruption of the scar tissue and a subsequent insignificant reduction of IOP or conversely to an extensive loss of the tissue resistance followed by a massive drop of the IOP. These observations have prompted surgeons to implement some modifications of the original technique to try and achieve a better control on the outcome.

Laspas et al⁵⁶ recently described a retrospective interventional case series of two groups of patients with failed trabeculectomies: the first group (23 eyes of 23 patients) underwent a typical needling procedure whereas the other group (23 eyes of 23 patients) was treated with a combination of needling and transconjunctival scleral flap sutures. The authors found that the percentage of hypotony and the percentage of complications related to hypotony (such as choroidal effusion) was 5 fold higher and 2 fold higher respectively in the sole needling group. Although the limited number of patients considered in the paper prevented any definite conclusions, the authors suggest that the use of transconjunctival scleral flap sutures in

patients with high risk profile for hypotony might be able to preempt a significant proportion of hypotony related complications.

Wilson et al⁵⁷ described a retrospective case series of 33 eyes of 30 patients who underwent a modified bleb needle technique. The main difference compared with the standard approach was the use of an anterior chamber maintainer. An advantage of that modification was that continuous infusion of BSS into the anterior chamber throughout the needling procedure allowed to receive an immediate feedback regarding the recovery of the drainage and to avoid an overtreatment with the risk of hypotony. The study compared favorably with previous similar ones: survival analysis showed an overall success in 64% of the patients at 12 months. Mean IOP at last follow-up was 14.3 ± 2.8 mmHg, significantly lower than the baseline pre-treatment IOP of 22.1 ± 9.24 mmHg ($p < 0.05$).

Dada et al⁵⁸ have applied advanced technologies like intraoperative OCT to the needling procedure in order to get a visualization of the scar tissue and to maneuver the needle more effectively at the level of the subconjunctival space and under the scleral flap until the anterior chamber.

BLEB NEEDLE REVISION (BNR): COMPLICATIONS

The entire spectrum of complications which may arise following a trabeculectomy may develop after a bleb needling revision. The most common complications are 5-FU related corneal epithelium toxicity and subconjunctival haemorrhage in the area of the bleb. The latter may increase the risk of failure of the procedure due to the incitement of scar tissue deposition. Other relatively infrequent complications are anterior uveitis, hyphema, shallowing of the anterior chamber, hypotony, serous choroidal detachment and hypotony maculopathy. More serious complications such as aqueous misdirection syndrome, loss of sight and bleb related infections are rare but also possible and should be recognized and treated promptly.

STUDY INTRODUCTION

Trabeculectomy still represents the first choice in the management of many types of glaucomas. Despite the improvement of the efficacy and safety of the procedure achieved over many years of refinement of the technique (including the introduction of antimetabolite) there is still a significant percentage of patients who fail to accomplish the desired target IOP. These patients may show signs of failure in the early postoperative time or less commonly many years after surgery. Subconjunctival injections of steroids or 5-FU, removal or adjustment of releasable sutures, laser suture lysis and self-massage of the eyeball may prove effective in reviving the bleb in the first month following the surgery, and sometimes even longer than that. However after all these steps have been attempted or when the bleb function deteriorates many months or years after surgery, the surgeon is faced with the decision of what to do next. One option is to “accept” the failure of the trabeculectomy and move forward to another treatment modality: IOP lowering eyedrops, trabeculectomy same-site revision, redo trabeculectomy, minimally invasive glaucoma surgery (so called MIGS, usually performed combined with phacoemulsification in phakic eyes), glaucoma drainage device (GDD) implantation or ciliary body ablation procedures. Another approach is to “refuse” the failure of the trabeculectomy and to try and rescue it performing one or more bleb needle revisions (BNRs). There is still controversy around the safety and efficacy of BNR. The scope of this study is to highlight the performance of this procedure in a large number of patients in a single centre, employing a consistent surgical technique to minimise the surgical-related confounding factors.

PATIENTS AND METHODS

Patients who underwent trabeculectomy bleb needle revision (BNR) with a consistent technique over 10 years (2004-2014) were retrospectively reviewed in a single centre (Moorfields Eye Hospital, NHS Trust, London, UK). Two-hundred and thirteen eyes of 212 patients were identified. Nine patients were excluded because the needling was performed with a technique not consistent with the others, 1 patient was removed from the list because needling was cancelled and 10 patients were excluded from the study for the lack of data on the

procedures. This led to a total number of 192 eyes of 192 patients. All the patients had at least one BNR done, whereas 52 eyes of 52 patients underwent two or more revision procedures.

The procedures were all performed in the theatre by different surgeons but following a consistent technique. After administration of a topical anesthetic (tetracaine hydrochloride 1%) and topical povidone iodine 5%, each eye was draped and an eye speculum was placed. A drop of vasoconstrictor (phenylephrine 2.5%) was instilled whenever the conjunctiva was deemed to be too hyperemic and therefore at greater risk of bleeding. An insulin syringe with a 30 gauge needle attached to it or a 25 gauge orange needle mounted on a tuberculin syringe were bent at the junction with the syringe and used for the needling (Figure 1). The conjunctiva was entered far superiorly towards the fornix with the help of a forceps. The bevel-up needle was then directed tangential to the episcleral surface and towards the bleb area until resistance was appreciated at the tip of the needle. The sharp tip and the cutting edges of the needle were then used to puncture and disrupt the fibrotic bands approached by means of back and forth and sweeping movements (type 1 needling). The endpoint of the procedure was an elevation of the bleb which corresponded to a softening of the eyeball. In cases where the outflow was deemed inadequate, the needle was advanced at the edges and under the scleral flap (type 2 needling) and if still not sufficient into the anterior chamber (type 3 needling). When the procedure was completed the needle was withdrawn and an injection of 0.1 to 0.2 ml of 5-FU (50 mg/ml) was delivered followed by one of 0.1 ml of steroid (dexamethasone or betamethasone).

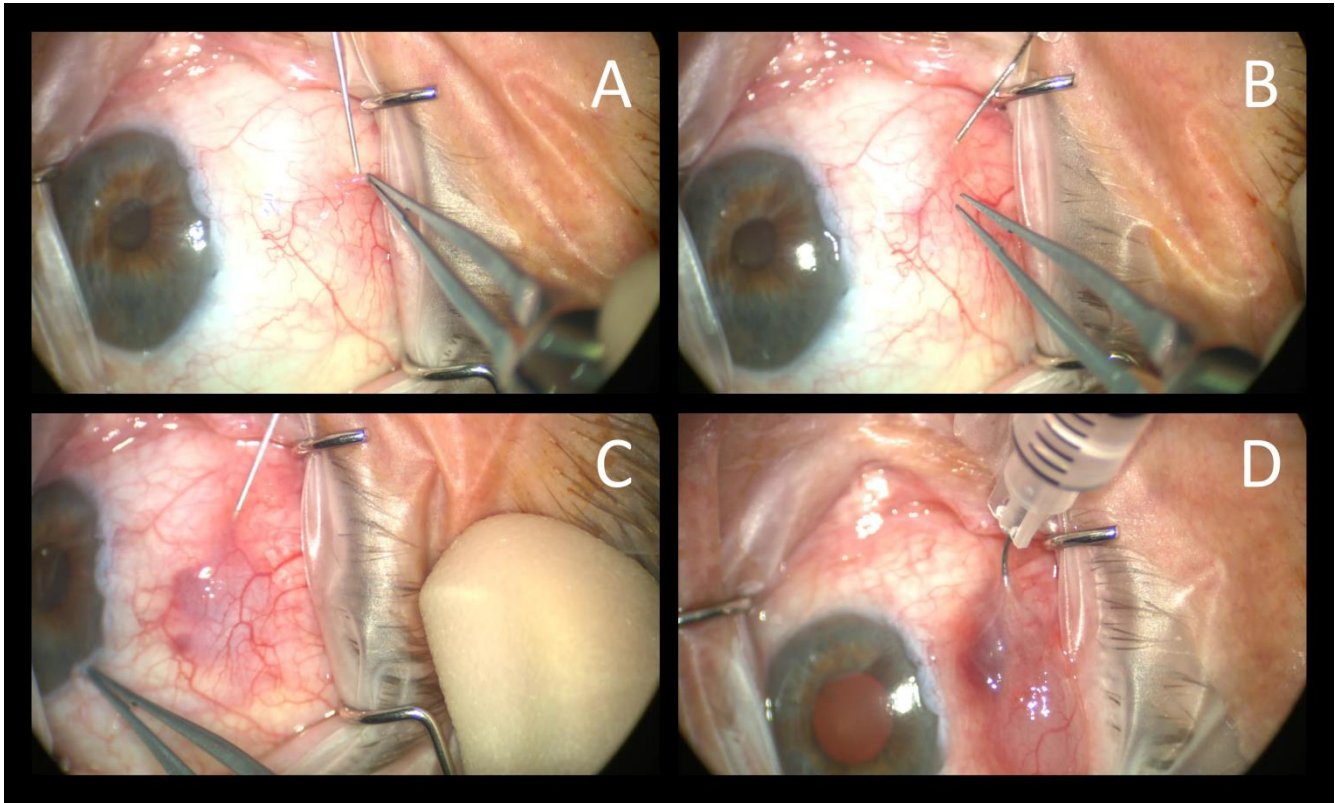


Figure 1 - Bleb needling revision (BNR). A) needle entering subconjunctival space; B) fibrotic adhesions disrupted by sweeping motion; C) subconjunctival bleed; D) injection of 5-FU.

Each patient was instructed to instill steroid drops (dexamethasone 0.1%) 2 hourly until review and antibiotic drops (chloramphenicol 0.5%) four times a day for two weeks. The topical steroid drops were tapered down according to the appearance of the bleb following the procedure. Additional 5-FU or steroid subconjunctival injections were administered in case of early signs of failure were spotted. The needling was repeated in patients in case of failures whenever the surgeon felt that a repeat procedure could have proved successful.

Three criteria for defining success were identified based on IOP reduction only: A) IOP equal or less than 21 mmHg and at least 20% reduction from baseline IOP; B) IOP equal or less than 18 mmHg and at least 25% reduction from baseline IOP; C) IOP equal or less than 15 mmHg and at least 30% reduction from baseline IOP. Potential risk factors for failure considered were age, ethnicity, lens status, interval between trabeculectomy and needle revision, pre-needling IOP and early post-needling IOP.

STATISTICAL ANALYSIS

Survival analysis with Kaplan-Meier curves was employed to investigate the probability of cumulative success based on the aforementioned three criteria. For the purposes of Kaplan-Meier plots, failure was defined as the occurrence of an IOP higher than the threshold set by the relevant criterion on two successive visits. If the IOP was above the threshold at the last follow-up visit, that was considered a failure as well.

Cox proportional hazard regression analysis was carried out to highlight the association between study factors and time to IOP failure. Student paired t-test was used to compare pre-needling and post-needling IOP and Wilcoxon signed-rank test to assess number of eyedrops before and after bleb needle revision.

The statistical analysis was conducted using R software (R software; provided in the public domain by the R Foundation for Statistical Computing, Vienna, Austria; available at www.r-project.org). A p value <0.05 was considered statistically significant.

RESULTS

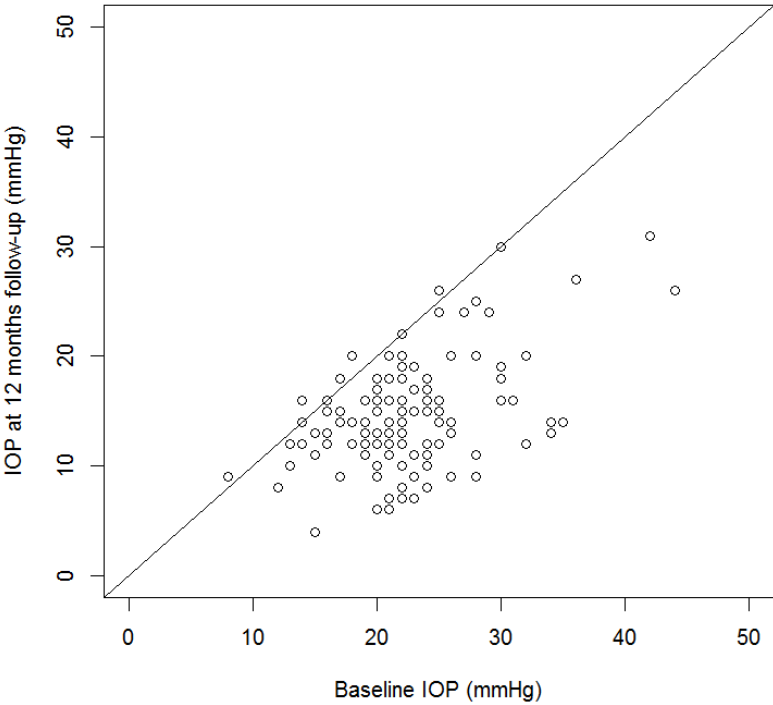
One hundred ninety-three eyes of 171 patients who underwent bleb needle revision were included in the study. The demographic and surgical data of the patients are summarised in Table 1. The mean age±standard deviation (SD) of the patients was 71.4±13.9 (range, 25-97 years). The median interval between the index filtration surgery (trabeculectomy) and the bleb needle revision was 27.5 months with a range of 21 days to 29,9 years. Median post-needling follow-up was 1.5 years (range 0-9 years). The patients were on a median of 2 IOP lowering agents (range 0-4); 32% of them were off glaucoma eyedrop prior to the bleb needle revision.

The mean pressure at baseline was 23.4 [±6.7 SD] mmHg with a range of 8 to 47 mmHg. After the revision the IOP decreased to 14.5 [±4.8 SD] mmHg at 1 year (range 4-31 mmHg), 13.09 [±4.0 SD] mmHg at 3 years (range 3-26 mmHg), and 15.3 [±6.0 SD] mmHg at 5 year follow-up (range 7-38 mmHg). The comparison between preoperative and postoperative IOP at different follow-up intervals is illustrated in Figures 2-5.

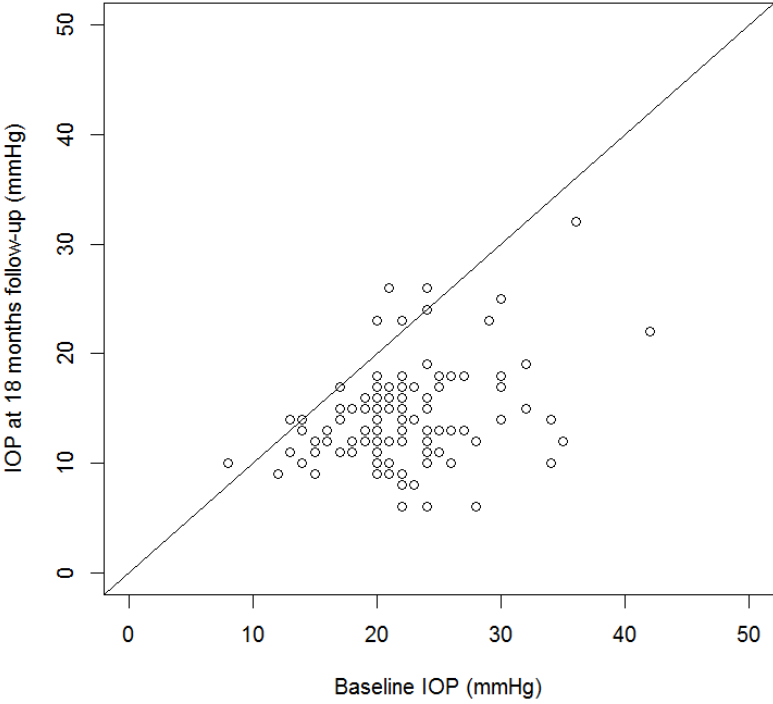
Patients / Eyes, n	171 / 193
Age, mean (SD)	71.4 (13.9)
Gender, n (F:M)	79 : 92
Eye, n (R:L)	100 : 93
Ethnicity	
White, n (%)	80 (46.8)
Black, n (%)	64 (37.4)
Asians, n (%)	21 (12.2)
Other, n (%)	6 (3.6)
Type of glaucoma	
POAG, n (%)	137 (70.9)
PACG, n (%)	14 (7.2)
Secondary glaucomas, n (%)	42 (21.9)
Lens Status	
Phakic, n (%)	103 (53.4)
Pseudophakic, n (%)	84 (45.6)
Missing data, n (%)	2 (1.0)
Ocular Biometry	
Axial length (mm), mean (SD)	23.8 (2.7)
Surgical data	
Antimetabolites during trabeculectomy, n (%)	157 (81.3)
Interval between trabeculectomy and bleb needle revision (days), mean (SD)	1967.8 (2349.9)
Type of needling	
Type 1, n (%)	65 (33.7)
Type 2, n (%)	43 (22.3)
Type 3, n (%)	52 (26.9)
Unknown, n (%)	33 (17.1)

Table 1 - Demographic and surgical characteristic of the cohort of patients.

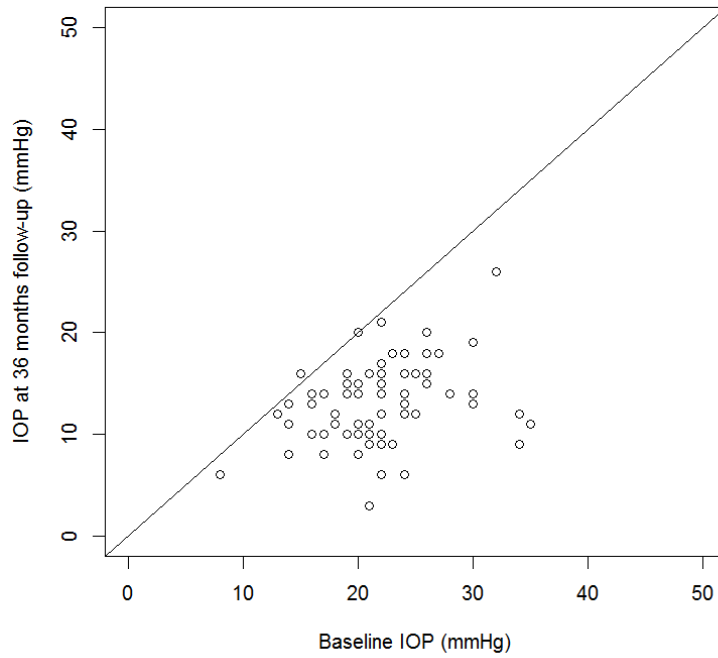
Scatterplot: baseline vs 12 months postop IOP



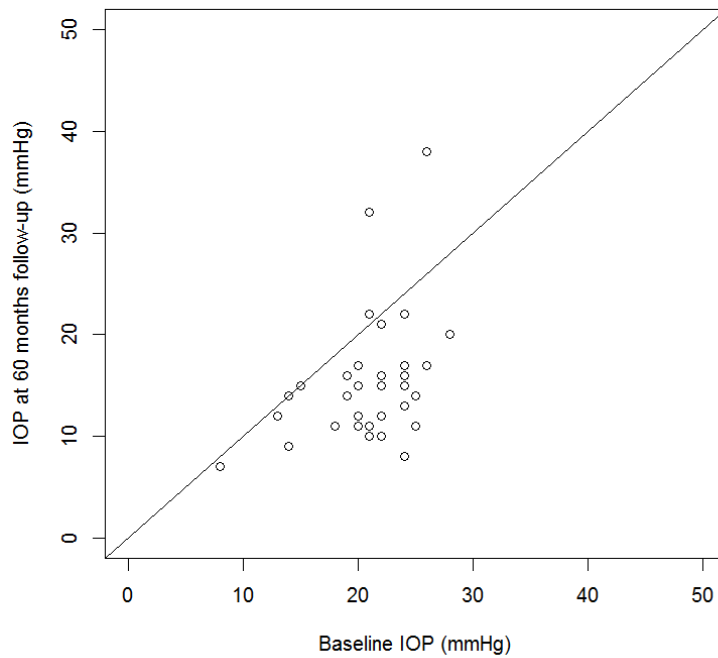
Scatterplot: baseline vs 18 months postop IOP



Scatterplot: baseline vs 36 months postop IOP



Scatterplot: baseline vs 60 months postop IOP



Figures 2-5 – Scatterplots showing baseline IOP against IOP at various follow-up points. Circles under the line of equity represent patients with lower IOP at follow-up.

Table 2 shows the IOP at baseline and at various follow-up points, together with a paired t-test to show the statistical significance of the IOP reduction after the procedure. Figure 6 shows a boxplot of the IOP against the follow-up time.

	IOP mmHg (SD)	P value
Baseline	23.4 (6.7)	-
1 Year	14.5 (4.8)	<0.001
2 Years	14.5 (5.1)	<0.001
3 Years	13.0 (4.0)	<0.001
4 Years	13.7 (4.5)	<0.001
5 Years	15.3 (6.0)	<0.001
6 Years	13.7 (4.2)	<0.001
7 Years	15.4 (5.7)	0.07
8 Years	14.1 (2.4)	0.04

Table 2 - IOP at baseline and at the various follow-up points with significance value.

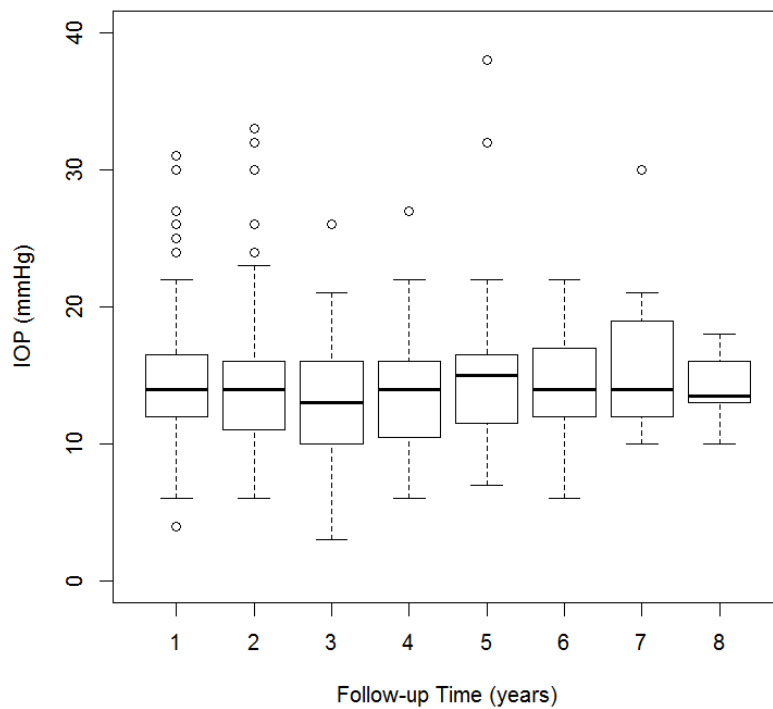


Figure 6 - Boxplot showing the IOP at various follow-up points with outliers.

The number of drops, indicated as individual agent, before and after the procedure is summarised in Table 4.

	n. agents	P value
Baseline	1.5 (1.3)	-
1 Year	0.8 (1.1)	<0.001
2 Years	1.3 (1.3)	0.14
3 Years	1.3 (1.4)	0.07
4 Years	1.2 (1.3)	0.05
5 Years	1.5 (1.5)	0.65
6 Years	1.5 (1.4)	0.51
7 Years	1.6 (1.4)	0.20
8 Years	2.3 (1.3)	0.77

Table 3 - Number of agents at baseline and at various follow-up points with significance value.

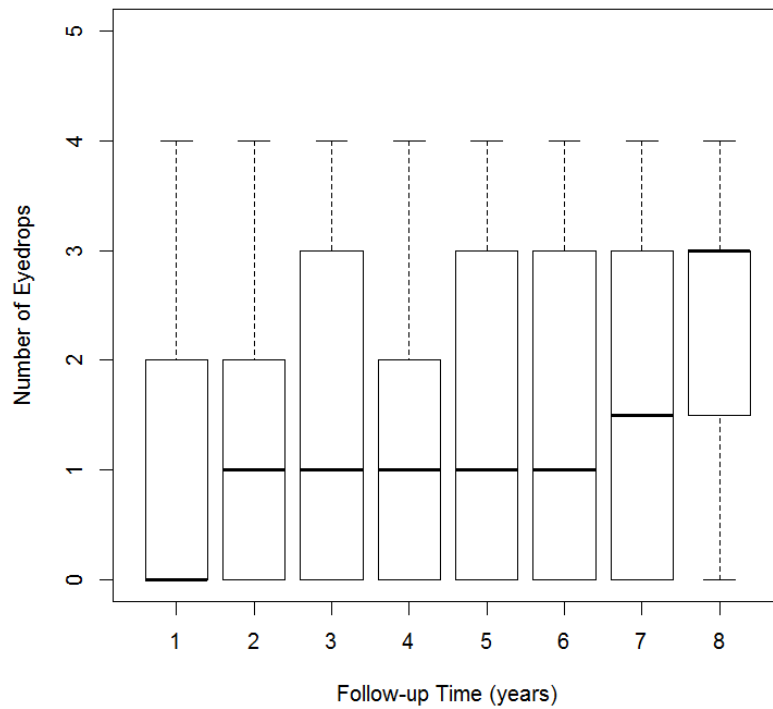


Figure 7 – Boxplot showing number of agents at various follow-up points.

The result of the survival analysis showed a probability of cumulative success at 1 year postoperatively of 63.0% [95% C.I. 55.4-69.7%], 51.1% [95% C.I. 43.5-58.2%] and 36.2% [95% C.I. 29.1-43.3%] according to criterion A, B and C respectively. The same analysis at 4 year follow-up showed the following figures: 49.8% [95% C.I. 41.0-57.9%], 29.6% [95% C.I. 21.7-37.8%] and 20.7% [95% C.I. 14.2-27.8%]. The Kaplan-Meier survival analysis is depicted in Figure 8.

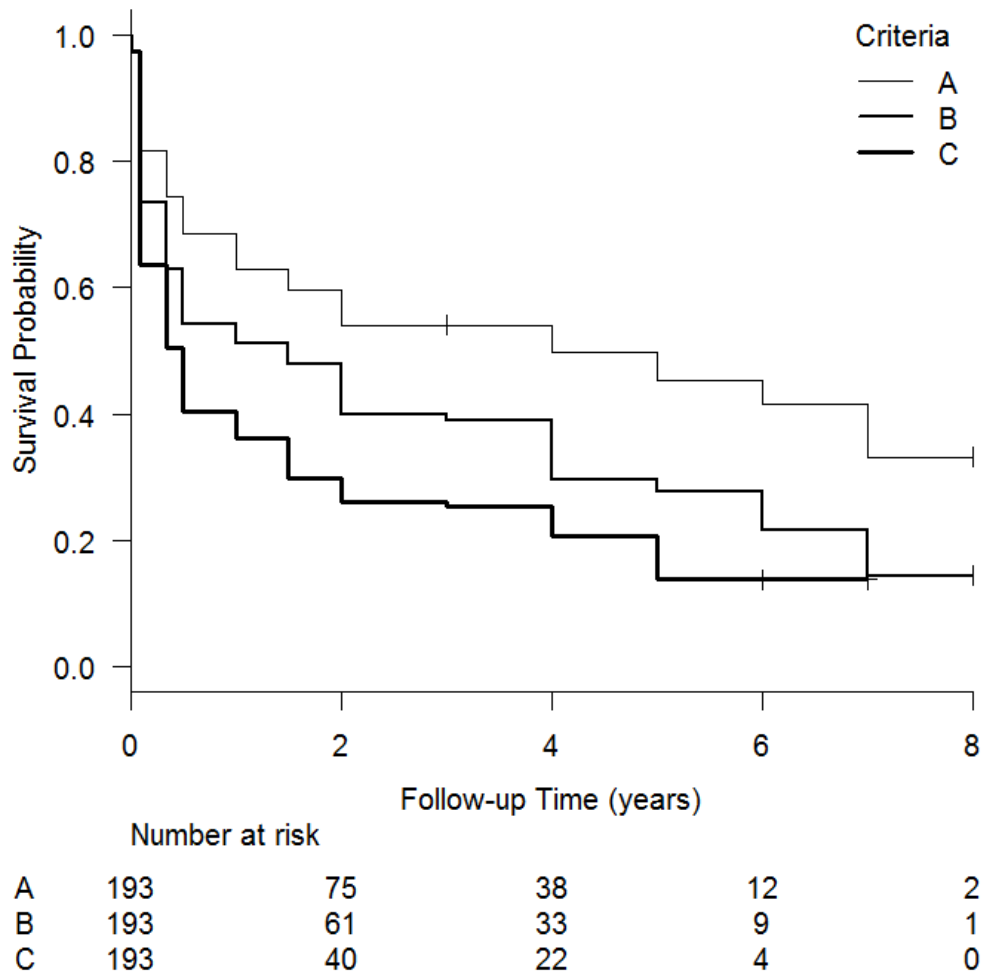


Figure 8 – Kaplan Meier plot illustrating survival probabilities according to the three criteria

The result of the Cox proportional hazards regression model showed that an immediate post needling IOP higher than 12 mmHg is associated with increased risk for failure for criterion B (HR=1.97 [95% C.I. 1.17-3.33], $p=0.010$) and C (HR=1.81 [95% C.I. 1.12-2.90], $p=0.013$) but not for criterion A. The relevant survival plots for

criterion B and C are shown in Figures 9 and 10. The log rank test was statistically significant for both plots (p=0.005 and p=0.014). The other predictors considered didn't reach statistical significance in the analysis.

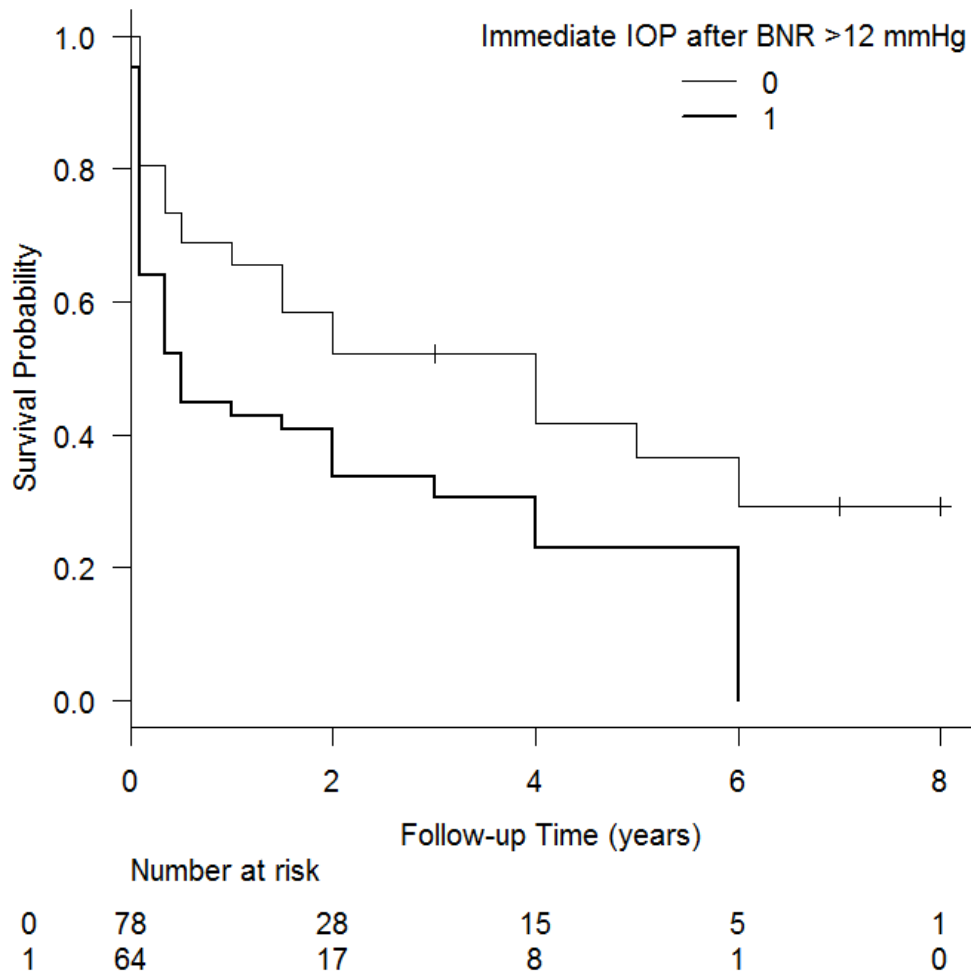


Figure 9 – Kaplan Meier plot showing survival probabilities according to criterion B considering the dichotomous variable immediate IOP after BNR >12 mmHg.

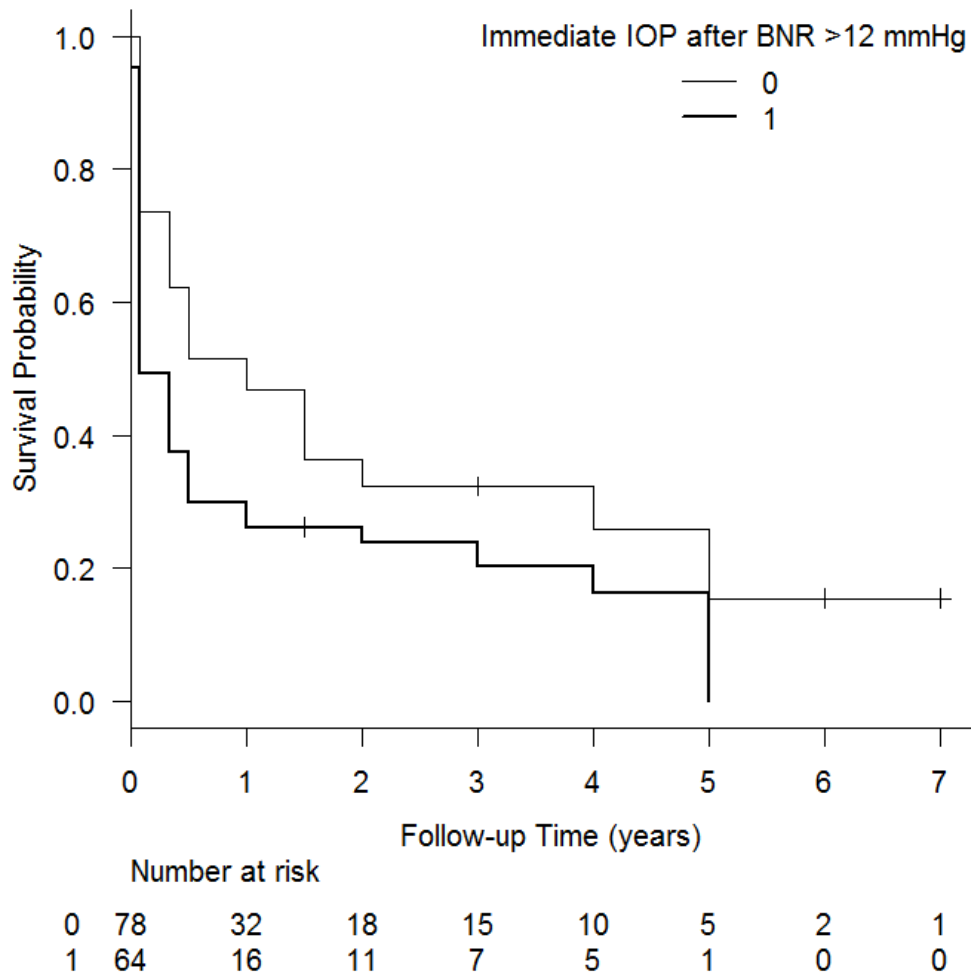


Figure 10 – Kaplan Meier plot showing survival probabilities according to criterion C considering the dichotomous variable immediate IOP after BNR >12 mmHg.

The complications which occurred as a consequence of bleb needling revision are listed in Table 4 (early postoperative time) and Table 5 (late postoperative time). Two patients lost 2 or more lines of vision at the last follow-up. One of them had hypotony and choroidal effusion which settled spontaneously, the other didn't experience any complication and the loss of vision was probably associated with a worsening of the glaucoma, the development of cataract or both these conditions.

Early postoperative complication	Number (%)
Subconjunctival haemorrhage	33 (17%)
Transient Hyphema	8 (4%)
Hypotony (IOP <6 mmHg)	9 (4.7%)
Serous choroidal detachment	2 (1%)
Shallow anterior chamber	5 (2.6%)
Other: corneal damage	3 (1.5%) :1 patient with punctate epithelial erosion, 1 with a corneal abrasion, and 1 with Descemet folds
high IOP (> 30 mmHg)	2 (1%)
bleed around iridectomy	1 (0.5%)

Table 4 –Early postoperative complications (within 3 months) following bleb needle revision.

Late postoperative complication	Number (%)
Late bleb leak	2 (1%)
Vitreous haemorrhage	2 (1%)
Acute anterior uveitis	3 (1.5%)
Chronic hypotony with hypotony maculopathy	1 (0.5%)
Wipe out	1 (20.5%)
Loss of ≥2 lines of vision (logMAR)	2 (1%)

Table 5 – Late postoperative complications (later than 3 months) following bleb needle revision.

DISCUSSION

Trabeculectomy is still the mainstay of glaucoma surgeries and the first line surgical treatment in the majority of glaucoma subtypes. Despite the fact the surgery proves successful in a remarkable number of cases, the failure rate is not negligible. In a recent retrospective multicentre study² assessing the IOP lowering

performance of trabeculectomy across different sites found that 13% of the patients failed to achieve the target IOP of ≤ 21 mmHg and a 20% reduction from baseline at 2 year follow-up despite the additional use of glaucoma eyedrops. Similarly 14% of the patients were classified of failure based on an IOP target of ≤ 18 mmHg and a 25% reduction from baseline at 2 years in spite of IOP lowering topical medications. For those patients there is a need for an additional intervention aimed to achieve a more suitable IOP. In this respect it would be ideal to resort to an intervention which would enhance the function of the existing trabeculectomy filter. That intervention should allow to achieve a more suitable IOP and to postpone to a later stage more invasive procedures. Bleb needle revision (BNR) of trabeculectomy is an ideal candidate for that purpose. Hence an increased awareness on the outcome of bleb needle revision is desirable, so that the clinician can then make his mindful choice based on the available scientific evidence and the overall clinical picture. A decisional algorithm could be implemented in which, after a failed trabeculectomy, further available options are considered on the base of their impact on the conjunctiva. In that respect, one would prefer to attempt a bleb needle revision prior to resort to more invasive procedures such as a redo trabeculectomy or a glaucoma drainage device insertion. The minimal invasive nature of bleb needle revision allows to spare the conjunctiva and ideally to minimise tissue disturbance and therefore to recruit less inflammatory cells and fibroblasts. The augmentation of the procedure with the antimetabolite 5-fluorouracil is meant to further keep the tissues as quiescent as possible.

Broadway et al reported outcome data on bleb needle revision in one of the largest prospective studies on this subject, including 101 eyes of 101 patients.⁵⁹ Almost a quarter of their patients had previous combined surgeries (cataract extraction and trabeculectomy), while the remaining had trabeculectomy alone. Fifty-seven eyes (56.4%) received an antifibrotic treatment perioperatively which consisted of 5-FU (44.5%), MMC (7.9%) or β -irradiation (4.0%). The authors describe success rates based on two criteria: IOP < 22 mmHg with less glaucoma medications (criterion 1) or more than 30% reduction from baseline IOP and less glaucoma medications (criterion 2). Kaplan-Meier analysis showed a survival rate of 75% and 56% at 1 year according to criterion 1 and 2 respectively. The outcomes of bleb needle revision in the study by Broadway et al seem better compared to the ones reported in this study (probability of survival of 63% at 1 year and 49.8% at 4 year according to criterion A, i.e. IOP ≤ 21 mmHg regardless of glaucoma eyedrops). However there are some differences between the studies which may have played a role in the dissimilar results. Broadway et al conducted a prospective study investigating the outcome of standardized bleb needling revision in eyes with failing or failed trabeculectomies. Thirty-three out of 101 eyes had redo needling done. Seventy-nine percent of the patients were Caucasian, 14% Afro-Caribbean and 7% Asian. Contrary to that the present study has a retrospective design and is focused on the outcome of single bleb needle revision. Forty-seven percent of the

patients were Caucasian, 37% were African or Afro-Caribbean and 12% were Asian (4% were coded as other ethnicities). The disparity in the design (prospective vs retrospective), the number of procedures per eye (multiple vs single), the percentage of pseudophakic eyes (16% vs 46%) and the different proportions of ethnicities may account at least partly for the outcomes achieved in the studies. In the Cox proportional hazards regression analysis this study found immediate post BNR IOP >12 mmHg as a risk factor for failure, but only for the more stringent criteria B and C. In the paper by Broadway et al a lower pre-needling IOP is associated with success for criterion 1 (IOP <22 mmHg), whereas the opposite is true for criterion 2 (IOP <30%). The authors highlight that an IOP lower than 11 mmHg immediately after the procedure reached a statistical significance as indicator of success according to criterion 1. Other factors known to be associated with increased risk of failure (young age, non-white ethnicity, previous cataract surgery and shorter interval between index surgery and needling) were not found to affect the outcome.

Rotchford et al reported the results of 5-FU augmented bleb needle revision in a prospective study involving a cohort of 81 patients.⁶⁰ Forty-six percent of them received an antimetabolite treatment (either 5-FU or MMC) at the time of the trabeculectomy and 12% had a combined phaco-trabeculectomy. The authors defined two criteria for success: IOP \leq 21 mmHg and 20% pressure reduction from baseline with the same number of eyedrops or less; IOP \leq 16 mmHg and 20% pressure reduction from baseline with the same number of eyedrops or less. The survival rates at 1 year were 54.3% and 53.1% according to criterion 1 and 2 respectively. At 3 years the survival analysis showed a probability of success of 31.9% and at 4 years of 13% with no difference between the two criteria. Similarly to what observed by Broadway et al⁵⁹, the authors found that an IOP \leq 10 mmHg immediately after the procedure is an indicator of success. Patients that required more than one needling had a worse outcome compared to those who underwent a single procedure. Interestingly when the survival rate of the subgroup of patients with a single needling procedure was analysed, the success at 2 years was 59%, compared to 54% found in this study. Once again the slight disparity of results may be attributed to some baseline characteristics, such as the higher proportion of patients who were pseudophakic and of black ethnicity in this study.

In a large retrospective study analyzing the outcome of 5-FU augmented bleb needling revision on a cohort of 175 Asian eyes, Tsai et al report the success rates of the two subgroups of POAG eyes (69%) and PACG eyes (31%).⁶¹ The definition of success was an IOP \leq 21 mmHg and \geq 6 mmHg. The success rates at 1 year was 89.5% and 87.5% at 1 year and 84.3% and 82.5% at 2 years for the POAG and PACG groups respectively. The log rank test showed no difference for the two subgroups in terms of survival probability. The survival rates in the paper by Tsai et al are particularly high compared to previous similar publications and to the present study. This may be related to the definition of success adopted by Tsai et al and to the fact that all the trabeculectomies were

augmented with MMC. The authors found that an higher IOP prior to the needling revision and the need for multiple procedures were predictors of failure.

The results of this study and illustrates that bleb needle revision is a viable option to successfully resurrect a considerable number of failed trabeculectomies. Same-site trabeculectomy represents an alternative approach of revision that entails a more invasive procedure. It is essentially a trabeculectomy performed following the previously dissected tissues. Hirunpatravong et al published the results of same-site trabeculectomy revision with adjunctive MMC in a retrospective study including 130 eyes of 117 patients.⁶² The authors defined three levels of qualified success (with and without drops) based on the following criteria: IOP \leq 18 mmHg and 20% reduction from baseline; IOP \leq 15 mmHg and 25% reduction from baseline and IOP \leq 12 mmHg and 30% reduction from baseline. In case where both the baseline IOP and the postoperative IOP were equal or lower than the set cut-off, a reduction of 2 or more meds was considered a success regardless of the percentage of reduction. The survival probabilities at 1, 3 and 5 years were 69.7%, 58.2% and 51.5% for the first criterion; 60.9%, 47.8% and 44.0% for the second criterion and 44.6%, 29.7% and 25.8% for the last criterion. Worse visual acuity at baseline and an interval from index surgery to revision of less than 3 years were found to be risk factors for all the criteria. The authors conclude that same-site trabeculectomy revision should be considered as a viable alternative to redo trabeculectomy (on a different site), particularly if the target IOP is in the mid or high teens. In comparison the survival rates in this study at 1,3 and 5 years were 51.1%, 39.0% and 27.7% for criterion B and 36.2%, 25.2% and 13.8% for criterion C. It is intuitive that a procedure such as same-site trabeculectomy revision, which involves the opening of the conjunctiva, the dissection of tissue and the application of the potent antimetabolite MMC, permits to achieve better results in terms of IOP reduction and survival rates. However this is at the cost of a longer, more invasive and potentially more prone to complication procedure.

In conclusion this study suggests that bleb needle revision is a safe and effective procedure which allows to rescue the trabeculectomy bleb function in a remarkable proportion of patients. It has the advantage of being quick and less invasive than other procedures. On the other hand the results of this study highlight that bleb needle revision proves to be more effective when the defined target IOP lies between the mid and the high teens. The presence of a significant lower mean IOP at the last follow-up point with a number of agents not significantly different from baseline suggests that this procedure is more effective at lowering IOP than at reducing the number of agents needed to control glaucoma progression.

Finally this study has limitations related to its retrospective design and potential selection bias. However the inclusion of procedures performed with a consistent technique hopefully minimized the variables related to the surgery.

REFERENCES

1. Cairns JE. Trabeculectomy. Preliminary report of a new method. *Am J Ophthalmol* 1968;66:673–9.
2. Kirwan JF, Lockwood AJ, Shah P, Macleod A, Broadway DC, King AJ, et al. Trabeculectomy in the 21st century: A multicenter analysis. *Ophthalmology* 2013;120:2532-2539.
3. Tham YC, Li X, Wong TY, Quigley HA, Aung T, Cheng CY. Global prevalence of glaucoma and projections of glaucoma burden through 2040: a systematic review and meta-analysis. *Ophthalmology*. 2014;121(11):2081-90.
4. Bonomi L, Marchini G, Marraffa M, et al. Prevalence of glaucoma and intraocular pressure distribution in a defined population. The Egna-Neumarkt Study. *Ophthalmology*. 1998;105(2):209-15.
5. Giuffrè G, Giammanco R, Dardanoni G, Ponte F. Prevalence of glaucoma and distribution of intraocular pressure in a population. The Casteldaccia Eye Study. *Acta Ophthalmol Scand*. 1995;73(3):222-5.
6. Cedrone C, Culasso F, Cesareo M, Zapelloni A, Cedrone P, Cerulli L. Prevalence of glaucoma in Ponza, Italy: a comparison with other studies. *Ophthalmic Epidemiol*. 1997;4(2):59-72.
7. Khaw P, Grehn F, Holló G, et al. A phase III study of subconjunctival human anti-transforming growth factor beta(2) monoclonal antibody (CAT-152) to prevent scarring after first-time trabeculectomy. *Ophthalmology*. 2007;114(10):1822-30.
8. Klink T, Rauch N, Klink J, Grehn F. Influence of conjunctival suture removal on the outcome of trabeculectomy. *Ophthalmologica*. 2009;223(2):116-23
9. Landers J, Martin K, Sarkies N, Bourne R, Watson P. A twenty-year follow-up study of trabeculectomy: risk factors and outcomes. *Ophthalmology*. 2012;119(4):694-702.
10. Chang L, Crowston JG, Cordeiro MF, Akbar AN, Khaw PT. The role of the immune system in conjunctival wound healing after glaucoma surgery. *Surv Ophthalmol*. 2000;45(1):49-68.
11. Nissen NN, Polverini PJ, Koch AE, Volin MV, Gamelli RL, Dipietro LA. Vascular endothelial growth factor mediates angiogenic activity during the proliferative phase of wound healing. *Am J Pathol*. 1998;152(6):1445-52.
12. Pierce GF, Mustoe TA, Lingelbach J, et al. Platelet-derived growth factor and transforming growth factor-beta enhance tissue repair activities by unique mechanisms. *J Cell Biol*. 1989;109(1):429-40.
13. Postlethwaite AE, Holness MA, Katai H, Raghow R. Human fibroblasts synthesize elevated levels of extracellular matrix proteins in response to interleukin 4. *J Clin Invest*. 1992;90(4):1479-85.
14. Desmoulière A, Redard M, Darby I, Gabbiani G. Apoptosis mediates the decrease in cellularity during the transition between granulation tissue and scar. *Am J Pathol*. 1995;146(1):56-66.

15. Leung EW, Medeiros FA, Weinreb RN. Prevalence of ocular surface disease in glaucoma patients. *J Glaucoma*. 2008;17(5):350-5.
16. Kolb M, Margetts PJ, Anthony DC, Pitossi F, Gauldie J. Transient expression of IL-1beta induces acute lung injury and chronic repair leading to pulmonary fibrosis. *J Clin Invest*. 2001;107(12):1529-36.
17. Wynn TA, Ramalingam TR. Mechanisms of fibrosis: therapeutic translation for fibrotic disease. *Nat Med*. 2012;18(7):1028-40.
18. Liu Y, Meyer C, Müller A, et al. IL-13 induces connective tissue growth factor in rat hepatic stellate cells via TGF- β -independent Smad signaling. *J Immunol*. 2011;187(5):2814-23.
19. Broadway DC, Grierson I, Stürmer J, Hitchings RA. Reversal of topical antiglaucoma medication effects on the conjunctiva. *Arch Ophthalmol*. 1996;114(3):262-7.
20. Breusegem C, Spielberg L, Van ginderdeuren R, et al. Preoperative nonsteroidal anti-inflammatory drug or steroid and outcomes after trabeculectomy: a randomized controlled trial. *Ophthalmology*. 2010;117(7):1324-30.
21. Saika S, Yamanaka O, Baba Y, et al. Accumulation of latent transforming growth factor-beta binding protein-1 and TGF beta 1 in extracellular matrix of filtering bleb and of cultured human subconjunctival fibroblasts. *Graefes Arch Clin Exp Ophthalmol*. 2001;239(3):234-41.
22. Serini G, Bochaton-piallat ML, Ropraz P, et al. The fibronectin domain ED-A is crucial for myofibroblastic phenotype induction by transforming growth factor-beta1. *J Cell Biol*. 1998;142(3):873-81.
23. Wallace DM, Murphy-ullrich JE, Downs JC, O'brien CJ. The role of matricellular proteins in glaucoma. *Matrix Biol*. 2014;37:174-82.
24. Fuchshofer R, Kottler UB, Ohlmann AV, et al. SPARC is expressed in scars of the Tenon's capsule and mediates scarring properties of human Tenon's fibroblasts in vitro. *Mol Vis*. 2011;17:177-85.
25. Takai Y, Tanito M, Ohira A. Multiplex cytokine analysis of aqueous humor in eyes with primary open-angle glaucoma, exfoliation glaucoma, and cataract. *Invest Ophthalmol Vis Sci*. 2012;53(1):241-7.
26. Lopilly park HY, Kim JH, Ahn MD, Park CK. Level of vascular endothelial growth factor in tenon tissue and results of glaucoma surgery. *Arch Ophthalmol*. 2012;130(6):685-9.
27. Sawada H, Fukuchi T, Tanaka T, Abe H. Tumor necrosis factor-alpha concentrations in the aqueous humor of patients with glaucoma. *Invest Ophthalmol Vis Sci*. 2010;51(2):903-6.
28. Dan J, Belyea D, Gertner G, Leshem I, Lusky M, Miskin R. Plasminogen activator inhibitor-1 in the aqueous humor of patients with and without glaucoma. *Arch Ophthalmol*. 2005;123(2):220-4.
29. Gardiner BS, Smith DW, Coote M, Crowston JG. Computational modeling of fluid flow and intra-ocular pressure following glaucoma surgery. *PLoS ONE*. 2010;5(10)

30. Ingber DE. Cellular mechanotransduction: putting all the pieces together again. *FASEB J*. 2006;20(7):811-27.
31. Ng CP, Hinz B, Swartz MA. Interstitial fluid flow induces myofibroblast differentiation and collagen alignment in vitro. *J Cell Sci*. 2005;118(Pt 20):4731-9.
32. Pedersen JA, Lichter S, Swartz MA. Cells in 3D matrices under interstitial flow: effects of extracellular matrix alignment on cell shear stress and drag forces. *J Biomech*. 2010;43(5):900-5.
33. Wilkins M, Indar A, Wormald R. Intra-operative mitomycin C for glaucoma surgery. *Cochrane Database Syst Rev*. 2005;(4):CD002897.
34. Green E, Wilkins M, Bunce C, Wormald R. 5-Fluorouracil for glaucoma surgery. *Cochrane Database Syst Rev*. 2014;(2):CD001132.
35. Yang JG, Deng Y, Zhou LX, Li XY, Sun PR, Sun NX. Overexpression of CDKN1B inhibits fibroblast proliferation in a rabbit model of experimental glaucoma filtration surgery. *Invest Ophthalmol Vis Sci*. 2013;54(1):343-52.
36. Xiong Q, Li Z, Li Z, et al. Anti-VEGF agents with or without antimetabolites in trabeculectomy for glaucoma: a meta-analysis. *PLoS ONE*. 2014;9(2):e88403.
37. Meyer-ter-vehn T, Sieprath S, Katzenberger B, Gebhardt S, Grehn F, Schlunck G. Contractility as a prerequisite for TGF-beta-induced myofibroblast transdifferentiation in human tenon fibroblasts. *Invest Ophthalmol Vis Sci*. 2006;47(11):4895-904.
38. Meyer-ter-vehn T, Katzenberger B, Han H, Grehn F, Schlunck G. Lovastatin inhibits TGF-beta-induced myofibroblast transdifferentiation in human tenon fibroblasts. *Invest Ophthalmol Vis Sci*. 2008;49(9):3955-60.
39. Van rooij E, Sutherland LB, Thatcher JE, et al. Dysregulation of microRNAs after myocardial infarction reveals a role of miR-29 in cardiac fibrosis. *Proc Natl Acad Sci USA*. 2008;105(35):13027-32.
40. Li N, Cui J, Duan X, Chen H, Fan F. Suppression of type I collagen expression by miR-29b via PI3K, Akt, and Sp1 pathway in human Tenon's fibroblasts. *Invest Ophthalmol Vis Sci*. 2012;53(3):1670-8.
41. Reibaldi A, Uva MG, Longo A. Nine-year follow-up of trabeculectomy with or without low-dosage mitomycin-c in primary open-angle glaucoma. *Br J Ophthalmol*. 2008;92(12):1666-70.
42. Rothman RF, Liebmann JM, Ritch R. Low-dose 5-fluorouracil trabeculectomy as initial surgery in uncomplicated glaucoma: long-term followup. *Ophthalmology*. 2000;107(6):1184-90.
43. Five-year follow-up of the Fluorouracil Filtering Surgery Study. The Fluorouracil Filtering Surgery Study Group. *Am J Ophthalmol*. 1996;121(4):349-66.
44. Broadway DC, Chang LP. Trabeculectomy, risk factors for failure and the preoperative state of the conjunctiva. *J Glaucoma*. 2001;10(3):237-49.

45. Dushinski R, Plevan E, Heidelberger C. The synthesis of 5 fluoro pyrimidines. *J Am Chem Soc* 1957; 79: 4559-60.
46. Abraham LM, Selva D, Casson R, Leibovitch I. The clinical applications of fluorouracil in ophthalmic practice. *Drugs*. 2007;67(2):237-55.
47. Five-year follow-up of the Fluorouracil Filtering Surgery Study. The Fluorouracil Filtering Surgery Study Group. *Am J Ophthalmol*. 1996;121(4):349-66.
48. Wudunn D, Cantor LB, Palanca-capistrano AM, et al. A prospective randomized trial comparing intraoperative 5-fluorouracil vs mitomycin C in primary trabeculectomy. *Am J Ophthalmol*. 2002;134(4):521-8.
49. Singh K, Mehta K, Shaikh NM, et al. Trabeculectomy with intraoperative mitomycin C versus 5-fluorouracil. Prospective randomized clinical trial. *Ophthalmology*. 2000;107(12):2305-9.
50. Smith S, D'amore PA, Dreyer EB. Comparative toxicity of mitomycin C and 5-fluorouracil in vitro. *Am J Ophthalmol*. 1994;118(3):332-7.
51. Traverso CE, Facino M, Murialdo U, Corazza M, Gandolfo E, Calabria G. Decreased corneal complications after no-reflux, low-dose 5 fluorouracil subconjunctival injection following trabeculectomy. *Int Ophthalmol*. 1994;18(4):247-50.
52. Healey PR, Crowston JG. Trypan blue identifies antimetabolite treatment area in trabeculectomy. *Br J Ophthalmol*. 2005;89(9):1152-6.
53. Wells AP, Ashraff NN, Hall RC, Purdie G. Comparison of two clinical Bleb grading systems. *Ophthalmology*. 2006;113(1):77-83.
54. King AJ. Classification of needling for trabeculectomy blebs. *Clin Experiment Ophthalmol*. 2016.
55. Yamamoto T, Sawada A, Mayama C, et al. The 5-year incidence of bleb-related infection and its risk factors after filtering surgeries with adjunctive mitomycin C: collaborative bleb-related infection incidence and treatment study 2. *Ophthalmology*. 2014;121(5):1001-6.
56. Laspas P, Culmann PD, Grus FH, et al. A New Method for Revision of Encapsulated Blebs after Trabeculectomy: Combination of Standard Bleb Needling with Transconjunctival Scleral Flap Sutures Prevents Early Postoperative Hypotony. *PLoS ONE*. 2016;11(6):e0157320.
57. Wilson ME, Gupta P, Tran KV, et al. Results From a Modified Bleb Needling Procedure With Continuous Infusion Performed in the Operating Room. *J Glaucoma*. 2016;25(9):720-6.
58. Dada T, Angmo D, Midha N, Sidhu T. Intraoperative Optical Coherence Tomography Guided Bleb Needling. *J Ophthalmic Vis Res*. 2016;11(4):452-454.

59. Broadway DC, Bloom PA, Bunce C, Thiagarajan M, Khaw PT. Needle revision of failing and failed trabeculectomy blebs with adjunctive 5-fluorouracil: survival analysis. *Ophthalmology*. 2004;111(4):665-73.
60. Rotchford AP, King AJ. Needling revision of trabeculectomies bleb morphology and long-term survival. *Ophthalmology*. 2008;115(7):1148-1153.e4.
61. Tsai AS, Boey PY, Htoon HM, Wong TT. Bleb needling outcomes for failed trabeculectomy blebs in Asian eyes: a 2-year follow up. *Int J Ophthalmol*. 2015;8(4):748-53.
62. Hirunpatravong P, Reza A, Romero P, et al. Same-site Trabeculectomy Revision for Failed Trabeculectomy: Outcomes and Risk Factors for Failure. *Am J Ophthalmol*. 2016;170:110-118.