

ALMA MATER STUDIORUM UNIVERSITA' DI BOLOGNA

DOTTORATO DI RICERCA IN

Scienze Mediche Generali e Dei Servizi

Ciclo XXIX Secondo Bando

Settore Concorsuale 06H1

Settore Scientifico-Disciplinare MED/40

Ultrasound prediction of the mode of delivery in the second stage of labor using the fetal head-symphysis distance

Presentata dal Dott.

ALY MOHAMED ALAAELDIN KAMALELDIN ALY YOUSSEF

Coordinatore Dottorato Chiar.mo Prof.

LUIGI BOLONDI

Relatore Chiar.mo Prof.

GIANLUIGI PILU

Esame finale anno 2017

INDEX

INTRODUCTION	3
1.1 Fetal head station and its engagement in maternal pelvis	3
1.2 Intrapartum translabial ultrasound.....	4
1.3 Saggital plane parameters.....	6
1.4 Axial plane parameters	10
1.5 Clinical use of the ultrasound parameters: definition of fetal head station	13
1.6 Clinical use of ultrasound parameters in prolonged labor.....	15
1.7 Three dimensional ultrasound (3D).....	17
1.8 A useful tool, but which parameter is better to use?	18
MATERIAL AND METHODS	20
RESULTS	23
DISCUSSION AND CONCLUSIONS	29
REFERENCES.....	33

INTRODUCTION

Clinical evaluation of fetal head station and its progression in the birth canal during the second stage of labor has proved to be an inaccurate and poorly reproducible method¹⁻³. The complementary use of intrapartum ultrasonography has been proposed in last few years to improve the objectivity of the clinical evaluation during labor, supporting the clinicians in the diagnosis of dystocia and in the delivery management^{2,4-6}. Moreover, the use of ultrasound in labor along with the clinical evaluation could be a useful tool for the training of doctors and midwives⁶.

The purpose of this introduction chapter is to provide a practical guide to the use of ultrasound parameters proposed in the literature for the assessment of the fetal head station and its monitoring during the second stage of labor.

1.1 Fetal head station and its engagement in maternal pelvis

The “station” is the level occupied by the fetal head in the birth canal and its classification is traditionally expressed as the distance between the leading part of the skull and a virtual plane passing through the ischial spines, as anatomical landmarks. The engagement of the fetal head is the moment in which the leading part of the fetal head (usually the parietal bone) reaches this plane, defined as “station 0”⁷. Clinical identification of this parameter by digital examination is very complicated, especially because the ischial spines are not always on the same plane, as demonstrated by several anatomical studies⁷⁻⁸.

The determination of the fetal head station has been proved to be highly subjective in a study by Dupuis et al.¹ using a birth simulator. The authors positioned a model reproducing the fetal head, provided with a sensor, in one of the 11 stations identified by the American College of Obstetricians and Gynecologists (ACOG) classification. Then, it was asked several operators to clinically examine

the position of the fetal head. The authors proved a variable percentage of errors ranging from 30 to 80%, depending on the station and the grade of operators' expertise. A misclassification of the station may lead to inappropriate clinical choices and potential complications during labor.

1.2 Intrapartum translabial ultrasound

The use of translabial ultrasound, also known as transperineal ultrasound for the fetal head station's assessment and progression in the second stage of labor has been an argument of great interest in recent years⁹⁻¹³.

During the translabial ultrasound exam the patient has to be in a semi-recumbent position, with hips and legs flexed, in order to obtain the images of the median sagittal and transverse plane.

In the median sagittal plane, the essential anatomic landmarks are (figure 1):

1. the pubic symphysis directed horizontally and displayed as an oval and echogenic image, conventionally oriented horizontally.
2. The fetal skull, which echoic boards has to be clearly identified
3. The "infrapubic line": a line passing perpendicular to the long axis of the pubic symphysis reaching the dorsal part of the birth canal.

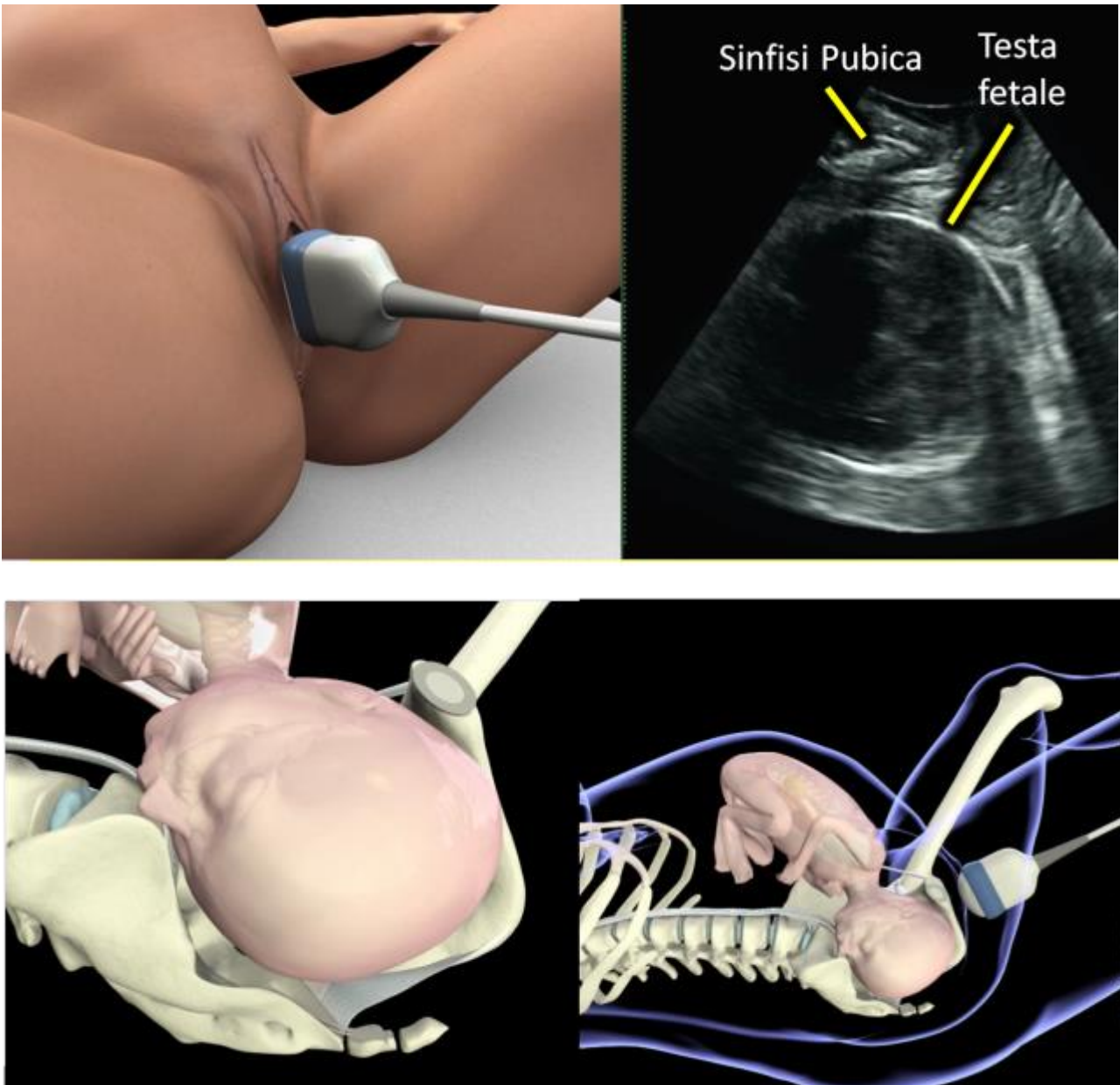


Figure 1. Representation of the transperineal ultrasound technique performed during labor.

In the mid-sagittal plane, we can study four parameters: the "Angle of Progression" (AOP), also known as angle of descent, the "Progression Distance" (PRD), the "Head Direction" (HD) and "Head-symphysis Distance" (HSD).

Rotating the translabial probe by 90° counterclockwise is possible to move from the median sagittal to a transverse or axial plane, on which we can evaluate other two parameters: the "Head Perineum Distance" (HPD) and the "Midline Angle" (MLA).

1.3 Sagittal plane parameters

1. The "Progression Angle" (AoP) or angle of descent of the fetal head, described by Barbera et al.¹⁴, is the angle formed between a line passing through the major axis of the pubic symphysis and a line traced from the inferior apex of the symphysis to the leading part of the fetal skull (Figure 2).
2. The "Progression Distance" (PRD) has been described for the first time in 2005 by Dietz et al.¹¹ and corresponds to the minimum distance between the infrapubic line (a line passing perpendicular to the long axis of the pubic symphysis) and the fetal skull (Figure 3).
3. "Head Direction" (HD) or direction of the fetal head, described for the first time by Henrich et al.¹⁰ corresponds to the direction of a line passing perpendicularly to the major diameter of the fetal head in the mid sagittal plane, considering the main pubic bone axis. It is defined as the angle between a vertical line passing from the inferior point of the symphysis (infrapubic line) and another line drawn perpendicular to the widest diameter of the fetal head in the infrapubic plane (Figure 4). This direction may be classified into three categories in relation to the major axis of the pubic symphysis: head down, horizontal and head up.

4. The "Head-symphysis Distance" (HSD) is a recently parameter described by Youssef et al.¹⁵ in 2013. It is a simple and reliable method to estimate the head station defining the distance between the lowest edge of the pubic symphysis and the nearest point of the fetal skull along the infrapubic line on midsagittal plane of the pelvis (Figure 5).

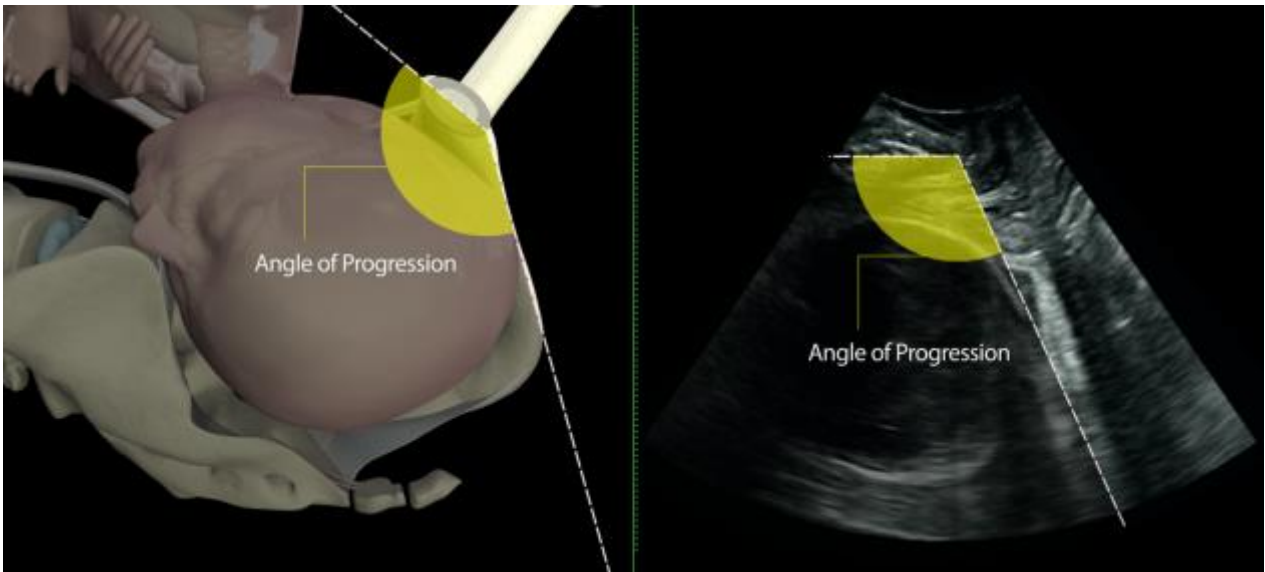


Figure 2. "Progression Angle" (AoP): Angle between the longitudinal axis of the pubic symphysis and a line which starts from its lower board and passes tangentially to the leading part of the fetal head.

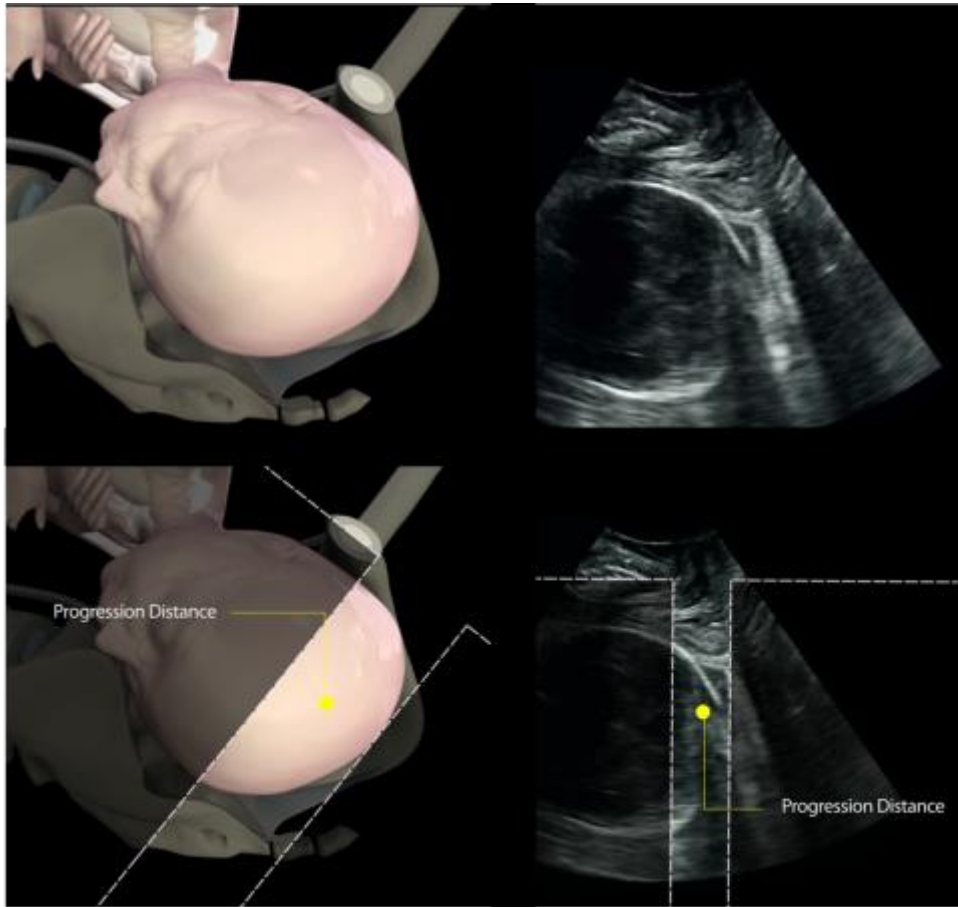


Figure 3. "Progression Distance" (PRD): minor traceable distance between the fetal skull and a line perpendicular to the lower edge of symphysis, the so-called infrapubic line.

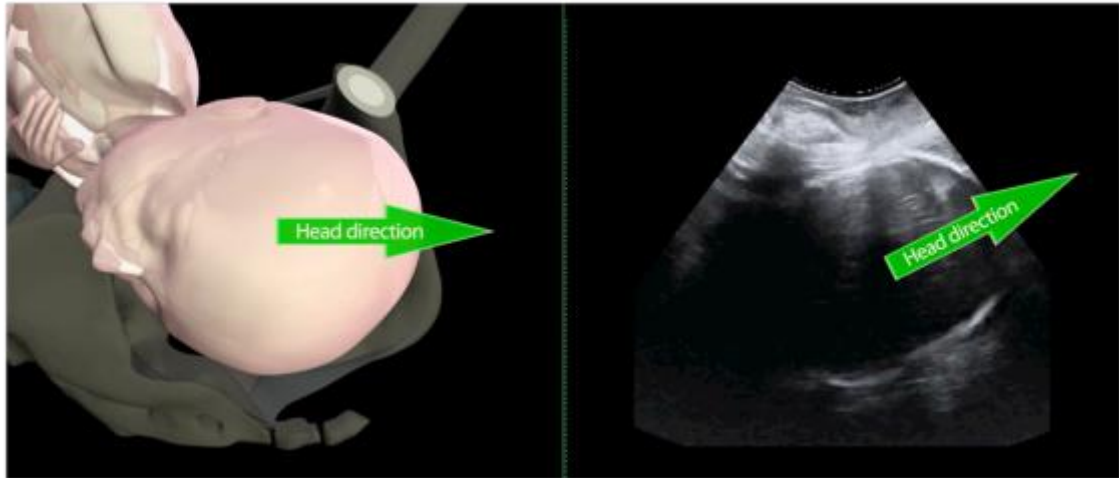


Figure 4. "Head Direction" (HD): direction of a line drawn perpendicular to the greater diameter of the fetal head, respect to infrapubic line.

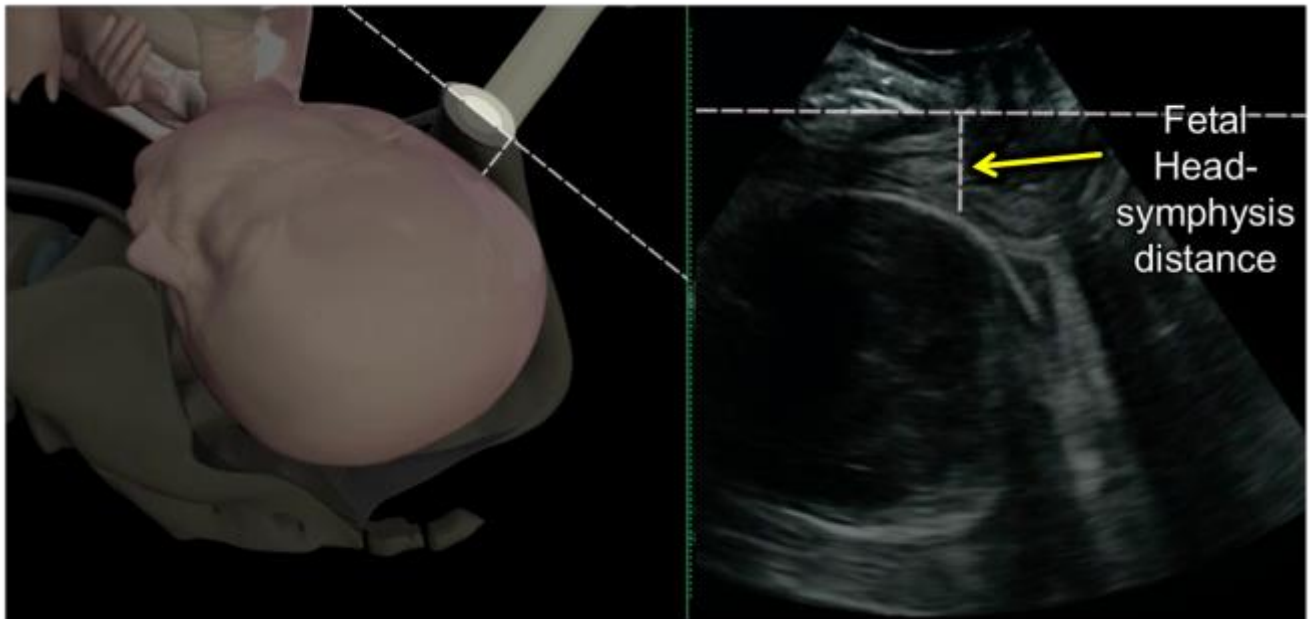


Figure 5. "Head-symphysis Distance" (HSD): distance between the lower edge of pubic bone and the nearest point of the fetal skull along the infrapubic line.

1.4 Axial plane parameters

1. The "Head Perineum Distance" (HPD) has been described by Eggebo et al.^{13,16} as the shortest distance between the outer border of the fetal skull and the perineum (Figure 6). The correct view of HPD is obtained placing the probe horizontally on the perineum and exerting a firm but soft compression on the labia. Move the probe lightly until you get the shortest distance.
2. The "Midline Angle" (MLA) corresponds to an angle formed by the midline of the fetal head and the anteroposterior diameter of the pubis (Figure 7). It has been described for the first time by Ghi et al.¹² in 2009 and it is the only parameter which evaluates the rotation of the fetal head. Rotating the probe by 90° counter clockwise you can obtain the correct visualization of MLA on the transversal plane with the right maternal side corresponding to the right side screen. In this way you can identify the echogenic line interposed between the

two cerebral hemispheres ("midline") and you can measure the angle formed by the midline and the antero-posterior diameter of the pubis (the so-called "Midline Angle").

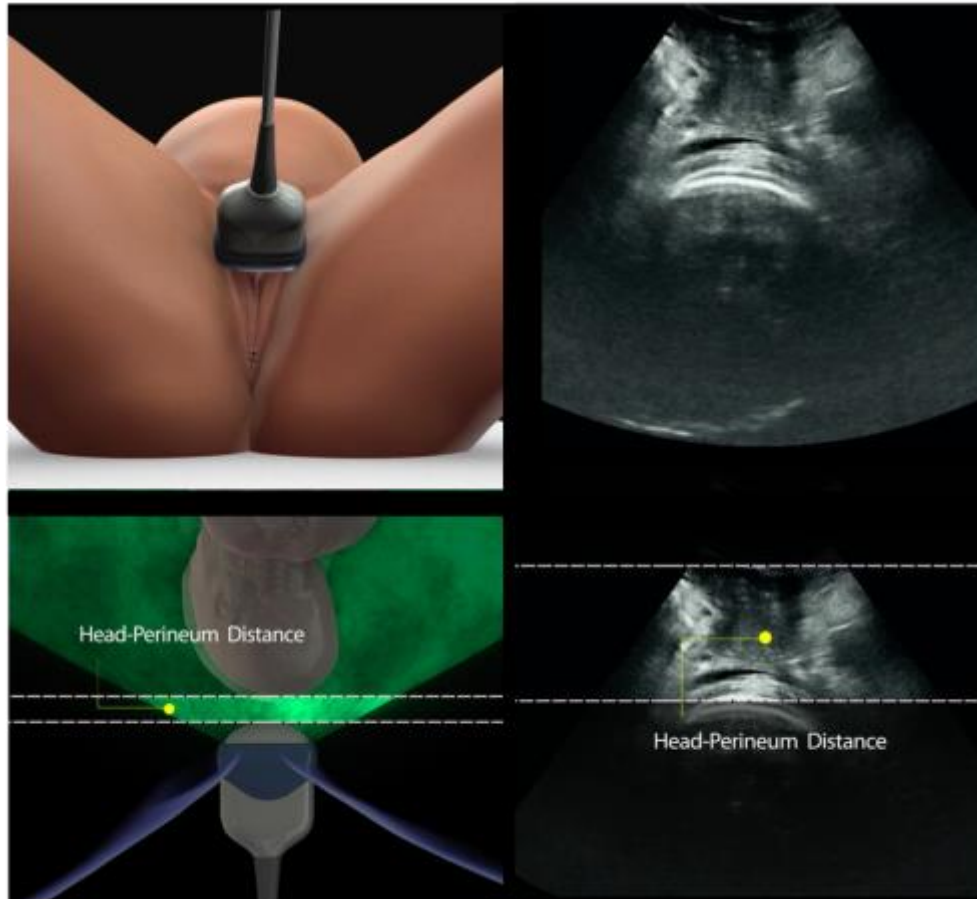


Figure 6. "Head Perineum Distance" (HPD): the shortest distance between the outer margin of the fetal skull and the perineal skin.

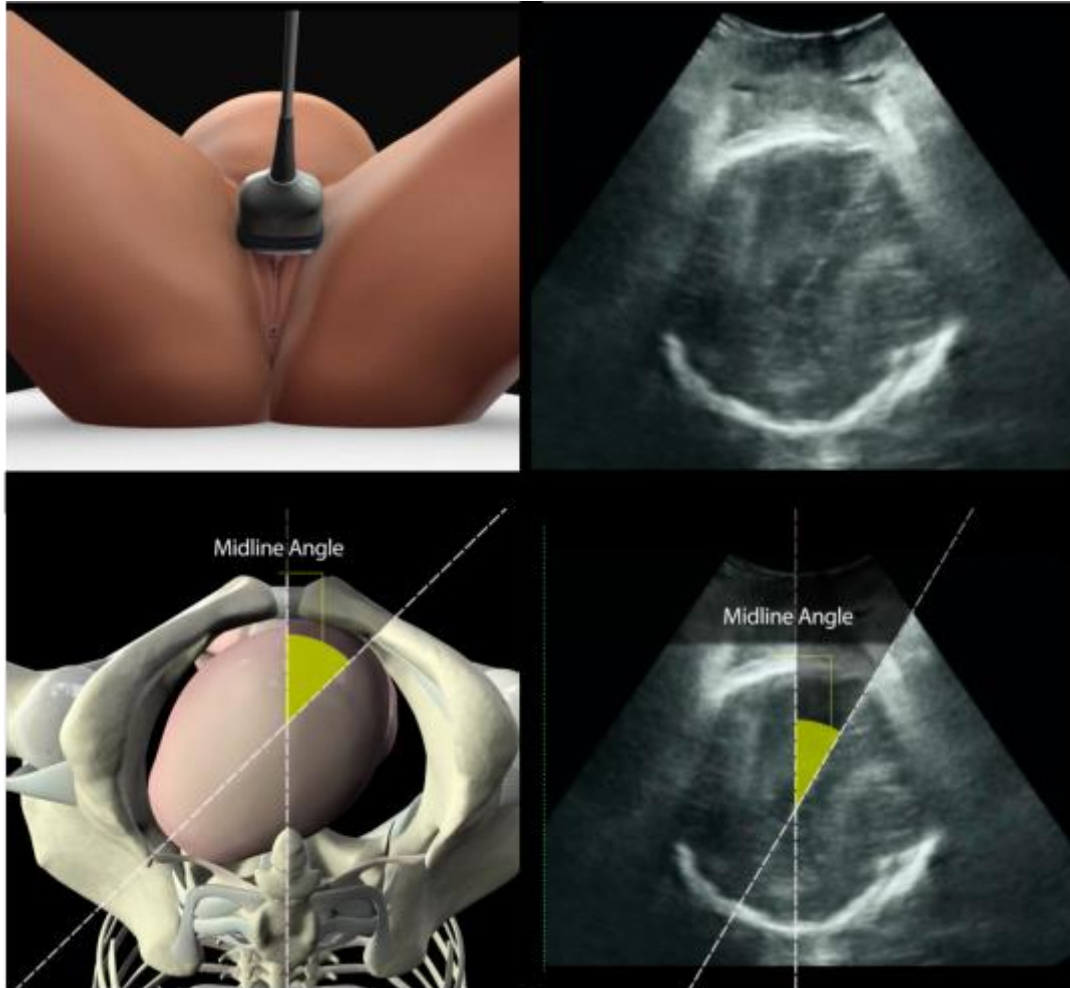


Figure 7. "Midline Angle" (MLA): angle between the anterior-posterior axis of the maternal pelvis and the midline of the fetal head.

1.5 Clinical use of the ultrasound parameters: definition of fetal head station

The ultrasound parameters used for the definition of the fetal head station on the mid sagittal plane are the Progression Distance (PD), the Head Direction (HD), the Progression Angle (PA) and the Head-symphysis Distance (HSD) and in the axial plane the Midline Angle (MLA).

The Progression Distance is one of the most useful parameter to assess the station of the fetal head; as shown by Dietz and Lanzarone¹¹ there is a significant correlation between the measurement of this parameter and the success of vaginal delivery¹⁷, as later confirmed by other Authors.

The Head Direction, that is the direction of the fetal head with respect to the infrapubic line, was studied in 2006 by Henrich et al.¹⁰: using Computed Tomography (CT), the authors have obtained three-dimensional images of female pelvis and have studied the relationship between the infrapubic line and other anatomic landmarks, proving that infrapubic line is almost 3 cm above a plane passing through the ischial spines. The Head Direction can be distinguished in three main degrees of orientation of the fetal head: head down, horizontal and head up. When the angle is 30° or more, it is considered 'head up'. For lines below 0°, the direction is 'head down'; all other angles are defined 'horizontal'¹². During the descent in the maternal pelvis the fetal head is also subject to a curvilinear movement upwards to the largest anteroposterior diameter of the pelvis. This is the so-called head up sign, an important sign associated with low station. Particularly, our group proved that when the head was directed downwards¹² the station was clinically estimated most frequently $\leq +1$ cm with respect to the ischial spines (44/57 [77.2%] cases). When the direction of the head was horizontal the station was most frequently between +1 and +2 cm (53/59 [89.8%] cases), and finally when it was upwards the estimated station was generally $\geq +3$ cm (46/52 [88.5%] cases). Several authors later confirmed the predictive value of this sign, as well as its intra- and inter-observer reproducibility¹⁷.

The Progression Angle is another accurate and reproducible parameter, and its reliability is not depending on the fetal head station or on the operator experience in performing ultrasound exam¹⁴.

¹⁷⁻¹⁹. By means of tomographic scans (TC) of non-pregnant women on the sagittal plane, Barbera et al.⁹ tried to determine which angle corresponds to the central point of a plane passing through the ischial spines, that is the station zero. The authors assigned predefined angles to each of the 11 possible stations (-5 to +5) and attributed to the zero station a progression angle corresponding to 99th and every other station had an AOP interval. They proved that AOP is a useful and reliable ultrasound parameter for the determination of the fetal head station.

Recently, Bamberg et al.²⁰ analyzed the correlation between AoP and the station of the fetal head established by means of magnetic resonance imaging (MRI), considered as the gold standard: they have detected a significative correlation between AoP and the distance between the fetal head and the maternal ischial spines. Although in this study fetal head was not engaged at the time of MRI or ultrasound, it was statistically assumed that station 0 corresponded to $AOP \geq 120^\circ$.

Our group reported a correlation between the angle of rotation between the fetal head and the anteroposterior axis of the birth canal (Midline Angle) and clinically evaluated station¹². Because the fetal head completes the internal rotation to pass the average inlet of the pelvis, it has been hypothesized that the degree of rotation of the head assessed by transperineal ultrasound correlates with the level of the presenting part. In fact, our data have shown that in fetuses in anterior occiput, the inability to identify the midline or the presence of a $\geq 45^\circ$ rotation is associated with a station $\leq +2$ cm in 98/103 cases (95.1%), while a rotation of less than 45° is associated to a station $\geq +3$ cm in the majority of digital explorations.

Recently, our group has suggested the use of the “Head-symphysis Distance” for the assessment of fetal station, showing a linear correlation between this ultrasound parameter and the level of the presenting part clinically evaluated, and an inverse correlation between the HSD and the progression angle¹⁵.

Through the analysis of 106 volumes acquired in nulliparous women at term of pregnancy with a prolonged first stage of labor, Tutschek et al.²¹ have shown that there is a good correlation between all the main transperineal ultrasound parameters, and in particular between Progression Angle (AOP), Head Perineum Distance (HPD) and Head-symphysis Distance (HSD). The authors proposed a conversion table for each of these ultrasound parameters with the head station digitally evaluated, expressed as the distance between the presented part and the ischial spines. The correlation between these ultrasound parameters and the fetal head station has been assessed exclusively in fetuses with occiput anterior. In fetuses with persistent posterior occiput, whose progression pattern in the birth canal follows a different trend, there is a lack of studies.

1.6 Clinical use of ultrasound parameters in prolonged labor

In case of prolonged labor is crucial to have a proper assessment of the progression of the fetal head in order to accurately identify which patients will require an operative delivery. With this purpose, Barbera et al.¹⁴ have tried to establish a correlation between success of vaginal birth and Progression Angle: in 88 patients at the end of pregnancy in the second stage of labor, the authors have shown that a AoP of 120° or more would always be associated with a subsequent spontaneous delivery .

In 2011 Torkildsen et al.²² tried to determine whether the Head Perineum Distance (HPD) and the progression Angle, measured by 2D and 3D ultrasonography in 110 patients, were able to predict the success of childbirth in nulliparous women with a prolonged first stage of labor. They found that these two parameters have a similar predictive value: in fact a HPD ≤ 40 mm correlates with a 93% probability of vaginal delivery, while a HPD > 50 mm with an 18% of success. Similarly, an AoP \geq

110° is associated with a probability of 87% of vaginal delivery, while an amplitude < 110° to a probability of success of 38%.

Tutschek et al.¹⁷ have then measured in 50 women in labor the changes of the fetal head station and its direction during maternal pushing. In particular, in the stations between -3 and -2 cm, the average descent during a contraction was 2.5 cm; between -2 and +2 cm and the average descent was 1 cm and between +2 and +3 cm was 2.2 cm. Moreover they noticed that in the upper part of the birth channel and until the +2 cm station, the direction of the fetal head varied by a head facing downwards to a horizontal direction, with a difference of about 18° at stations between +2 and +3 cm, both during contraction and at rest. In addition, they demonstrated by transperineal ultrasonography that variations of the progression distance > 1.5 cm, of the head direction > 20% and of the angle of progression > 120° under maternal pushing were related to a higher and faster probability of vaginal delivery; in particular for stations $\geq +2$ cm (n = 23) the average time from childbirth was 1h and 14 min, while in the stations $\leq +2$ cm the average time from birth was 27 min.

Our group²³ conducted a study with the purpose of comparing the variations of the Midline Angle and the Progression Angle in the second stage of labor, in relation to the mode of delivery. Using 3D transperineal ultrasonography, in 71 nulliparous women were acquired seriate volumes every 20 minutes from the beginning of the second stage (T1, T2, T3 ...). In the study group 58 women gave birth spontaneously (group A) and 13 with operative delivery (group B) (8 with vacuum extraction and 5 by caesarean section). Compared with the group B, group A had a greater AoP at T1 ($140.0 \pm 20,2^\circ$ vs $122 \pm 16,7^\circ$; P = 0.010) and T2 ($149.7 \pm 20.7^\circ$ vs $126.9 \pm 17,5^\circ$; P = 0.006) and a lower MLA at the T3 time ($21.2 \pm 11,7^\circ$ vs $40.8 \pm 27,9^\circ$; P = 0.043), T4 ($18.2 \pm 15,0^\circ$ vs $47.4 \pm 29,6^\circ$; P = 0.020) and finally at T5 ($18.3 \pm 6,0^\circ$ vs $34.7 \pm 4,2^\circ$; P = 0.034). To sum up, cases with a greater AoP at the beginning of the second stage of labor and a minor MLA in the later stages, have a higher probability

of spontaneous delivery. At multiple logistic regression analysis both AoP and MLA are shown to be independently associated with operative delivery (OR = 0.955 and OR = 1.018, respectively).

In the same series, it has been demonstrated that the patients who give birth within 60 minutes have angle of progression values significantly greater than those that deliver beyond this time. Moreover, by measuring the angle of progression at the onset of the expulsive period has been possible to estimate the interval in minutes between the start of the pushing and childbirth, and in particular the deliver was more rapid in those patients with wider progression angle. This could be very useful for those women in which the possibility of a long expulsion period can be clinically inadvisable for pre-existing risk conditions (for example cardiac or ocular pathologies of pregnant women).

1.7 Three dimensional ultrasound (3D)

As previously mentioned, the main ultrasound parameters used for the assessment of labor have shown a good reproducibility both inter- and intra-observer^{13, 14, 19}.

However, it was also emphasized the possibility that a transperineal ultrasound performed in real time may entail a certain variability of the parameters described so far, due to some inherent limitations to the technique²⁴. This can be due to several factors, in particular the angle of insonation compared to the pubic bone, which can significantly alter the measurements²⁵. Therefore it has been proposed the use of 3D ultrasound: this technique offers some advantages, including the possibility of obtaining a multiplanar reconstruction of the birth canal. This entails an easier standardization of plans in which carry out the measurements and a greater reproducibility of the results. The chance to benefit from a greater degree of standardization could make it even easier and therefore more widespread the use of ultrasound for the evaluation of the progression of the presenting part.

Molina et al.¹⁸ evaluated the direction of the fetal head, the "Midline Angle", the progression of distance and the angle of progression in 50 women using the 3D ultrasound and they showed that between these parameters the angle of progression would have the best reproducibility intra- and inter-observer. Even our group²⁵, analyzed 30 volumes acquired during labor and showed a good reproducibility among all the considered parameters (fetal head direction, angle of progression and progression distance), with the exception of Midline Angle. At the Bland-Altman analysis, the AoP and the progression distance parameters showed the highest reproducibility at 3D ultrasound.

Recently also the HSD has been studied both by means of three-dimensional (3D) ultrasound and by traditional 2D ultrasound, showing a good reproducibility, both intra- and inter-observer and an excellent correlation of the measured values with the two methods, in particular in the lowest fetal head stations (ICC 0.949, 95% CI: 0.914 to 0.984)^{15, 26}. This confirms the chance to use this parameter in the monitoring of fetal head descent even if a transducer with 3D technique is not available.

A further advantage of 3D ultrasound compared to the traditional 2D, is the possibility of obtaining sagittal and axial images on which to measure the various ultrasound parameters of interest as a result of a single and rapid acquisition. This can be an inexhaustible source of data, allowing a retrospective evaluation of new parameters and a better quality control.

1.8 A useful tool, but which parameter is better to use?

Despite the rise of the number of studies published about intrapartum ultrasound in the last few years, there is still not an evidence about which is the best ultrasound parameter in the evaluation of fetal head station and of fetal head progression during labor.

About this topic, a questionnaire has been proposed among the participants of an ultrasound and prenatal medicine course²⁷: it was found that the most common use of intra-partum ultrasound is

for the determination of occiput position; less widespread is the use of ultrasound in order to evaluate the station of the fetal head or monitor its progression during labour. The three main obstacles to the use of ultrasound in labour were: first the accessibility of the ultrasound machines (less than half of respondents have an ultrasound machine always available in the delivery room), in the second instance the lack of convincing data about the usefulness of this type of measurements and, finally, the complexity of the ultrasound parameters suggested.

This emphasizes the need to use in clinical practice simple and reproducible parameters; from this point of view, the fetal head-symphysis distance (HSD) seems to be one of the most promising parameters²⁸.

MATERIAL AND METHODS

The study was a retrospective analysis of ultrasound volumes obtained as part of a recently published study²³. In all, 3760 women delivered at Sant'Orsola-Malpighi university hospital between November 2010 and November 2011 were eligible for the study, i.e. nulliparous, with a live singleton pregnancy in cephalic presentation, at gestational age of more than 37 completed weeks and in active labor (defined as cervical dilatation of 3 or more cm and regular uterine contractions). Women were prospectively recruited when a trained investigator (with 3 or more years of experience in obstetric ultrasound) was available in the labor ward. The obstetrician performing the ultrasound examination was present in the labor ward exclusively for this aim, and was not aware of clinical examination results. Women were excluded if cesarean section or vacuum extraction was performed solely because of abnormal fetal monitoring or if cesarean delivery was performed in the first stage. Vacuum extraction was the only type of instrumental delivery used. Of the 1540 women thus selected, 76 were enrolled for the purpose of the head-progression study²³. Of these, three were excluded because of operative delivery for an abnormal fetal heart trace and two because of cesarean delivery before full cervical dilatation. The main reason for non-inclusion of further women was the unavailability of an investigator in the labor ward. From the 71 women finally recruited, we acquired and subsequently analyzed 174 three-dimensional intrapartum transperineal ultrasound volumes. All volumes initially obtained in were retrospectively analyzed in the present material²³.

Three dimensional (3D) ultrasound volumes acquisition, saving and analysis

Three dimensional (3D) ultrasound volumes were acquired translabially in the midsagittal plane as previously described²⁵, at the beginning of the active second stage (T1), and every 20 minutes thereafter (T2, T3, T4, T5, and T6) until delivery, whenever possible. All volumes were acquired in the absence of maternal pushing and uterine contractions. Volume analysis was performed after

delivery by an operator blinded to labor outcome. All 3D volumes were transferred to a PC equipped with dedicated software (Sono-VCAD labor, 4D view 9.0, GE Healthcare, Zipf, Austria) for off-line analysis. Each volume was analyzed in the multiplanar mode where, in accordance with the acquisition technique, the sagittal plane was displayed on Plane A, and the axial and the coronal planes on planes (B) and (C), respectively. Volume alignment was obtained using the urethra and symphysis pubis as reference points as previously described²⁵. Subsequently, the fetal head-symphysis distance (HSD), defined as the distance between the lower border symphysis pubis and the nearest point of the fetal skull along a line passing perpendicular to the long axis of the symphysis pubis and tangential to its lower border, was measured²⁹. For the purpose of the first study²³, other two intrapartum ultrasonographic parameters, namely the angle of progression^{14,29}, defined as the angle between the longitudinal axis of the pubic bone and a line joining the lowest edge of the pubis to the lowest convexity of fetal skull, and the midline angle¹² defined as the angle between the antero-posterior axis of maternal pelvis and the midline of the fetal brain, had been measured for the same acquisitions.

Statistics

Mean, standard deviation (SD) and frequencies were used as descriptive values. HSD was compared between women who had a spontaneous vaginal delivery compared to those who underwent operative delivery (including vacuum and cesarean delivery) by means of the Kruskal-Wallis and the Fisher's exact tests. The relation between HSD and angle of progression was analyzed by means of the general linear model analysis. In order to investigate the independence of HSD from a set of potential associated factors studied in the previous analysis of the present population²³, two stepwise forward multivariate logistic regressions were carried out considering HSD together with the ultrasonographic parameters (angle of progression and midline angle) only, as well as HSD together with the overall set of the variables previously studied. Logistic regression analyses were

performed by pooling the overall set of ultrasonographic volumes (n=174). The variables taken into account in the multivariate analyses were: HSD, angle of progression and midline angle as ultrasonographic parameters, epidural analgesia, maternal age, maternal body mass index (BMI), oxytocin administration, and gestational age as maternal and intrapartum variables²³. The odds ratios (ORs), computed by logistic regression together with their 95% confidence intervals (CI), were used to compute a score that could be potentially useful in the prediction of an operative delivery. The accuracy of such a score was evaluated by means of the area under the receiver operating characteristic (ROC) curve (AUC). The standard error of the AUC was also estimated to compare (by standardized normal distribution z test) different computed scores based on different sets of variables. The best cut-off of the ROC curve was evaluated by means a maximum likelihood method (15). Data were analyzed by using the SPSS (version 13.0 for Windows) and 2-tailed p-values <0.05 were considered significant.

Ethics

The study protocol was approved by the local Ethical Committee of Sant'Orsola-Malpighi Hospital and a consent form signed at recruitment was obtained from each eligible patient. The study protocol conforms to the ethical guidelines of the "World Medical Association (WMA) Declaration of Helsinki-Ethical Principles for Medical Research Involving Human Subjects" adopted by the 18th WMA General Assembly, Helsinki, Finland, June 1964 and amended by the 59th WMA General Assembly, Seoul, South Korea, October 2008

RESULTS

Among the women 58 (81.7%) had a spontaneous vaginal delivery and 13 (18.3%) underwent operative delivery (8 vacuum and 5 cesarean deliveries), with a total number of 174 3D-volume acquisitions. The demographic and clinical characteristics of the women have been previously published²³.

A graphic representation of the HSD data on individual patients by mode of delivery are displayed in Figure 8, while measurements of HSD are shown in Table 1.

Table 1: Fetal head-symphysis distance (HSD) at different time intervals according to the mode of delivery.

	Fetal head-symphysis distance (HSD, in mm)		
	Spontaneous vaginal delivery	Operative delivery	<i>p</i> value*
T1 (n=71; A: n=58, B: n=13)	15.8±4.6	23.0±7.2	<0.001
T2 (n=52; A: n=42, B: n=10)	12.6±3.7	21.0±6.4	<0.001
T3 (n=27; A: n=19, B: n=8)	12.1±3.2	16.4±5.0	0.025
T4 (n=15; A: n=10, B: n=5)	10.5±4.6	13.8±4.8	0.176
T5 (n=7; A: n=3, B: n=4)	10.8±4.9	14.3±2.5	0.285
T6 (n=2; A: n=1, B: n=1)	13.0	17.0	0.317

HSD is expressed as mean±SD

T1 is the scan at the beginning of the active second stage. The following scans are at 20 minute-intervals (i.e., T2, T3, T4, T5 and T6 are at 20, 40, 60, 80, and 100 minutes from the beginning of the active second stage, respectively)

*Kruskal-Wallis test

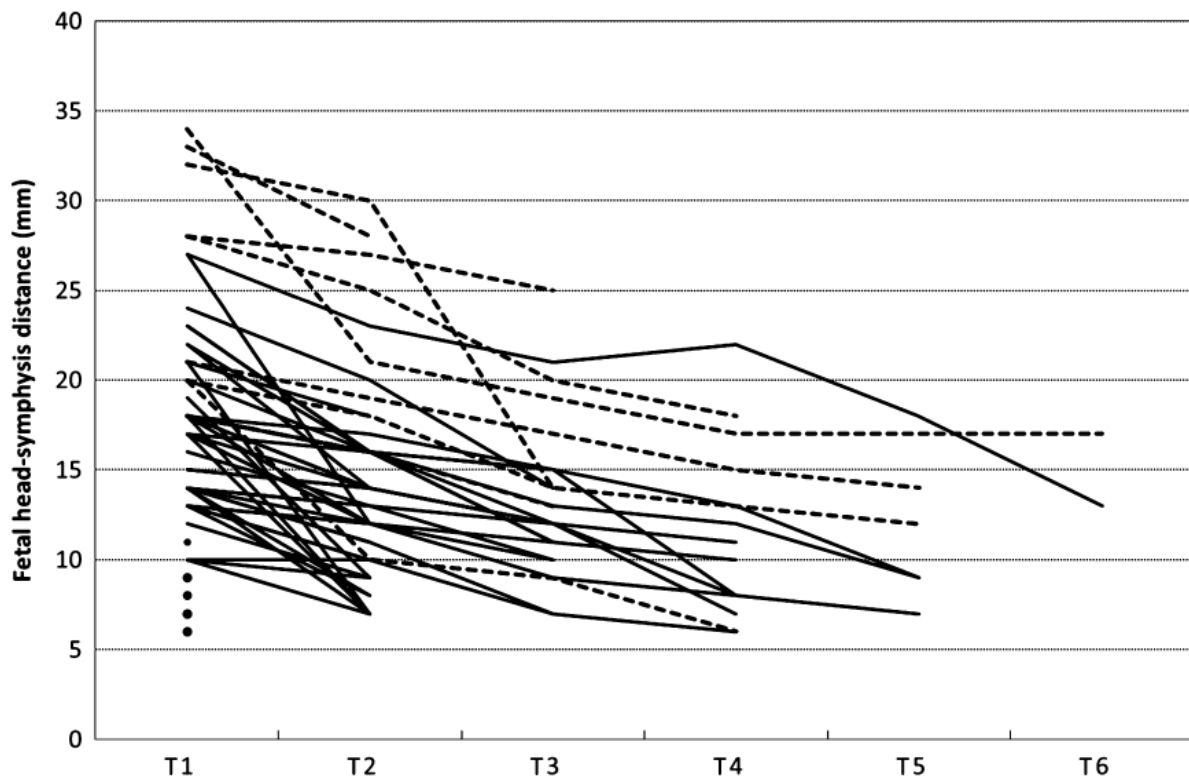


Figure 8. Time course of the fetal head-symphysis distance (HSD) data on individual patients according to the mode of delivery. Solid lines represent women with spontaneous vaginal delivery; dotted lines represent women with operative deliveries. T1 = scan at the beginning of the active second stage. Following scans are at 20 minute-intervals (T2, T3, T4, T5 and T6 at 20, 40, 60, 80, 100 min from the beginning of the active second stage). Women represented as solid dots at T1 are those who delivered <20 minutes after T1 (based on only one HSD value). All women had spontaneous vaginal delivery.

When compared to women who underwent operative delivery, women in the spontaneous vaginal delivery group had a significantly smaller HSD at T1, T2, and T3. The values were smaller even at T4, T5 and T6, but the differences were not significant. The ROC curves estimating the accuracy of HSD to predict operative delivery are shown in figure 9 and the values of the areas under the ROC curves at different scan times are reported in Table 2.

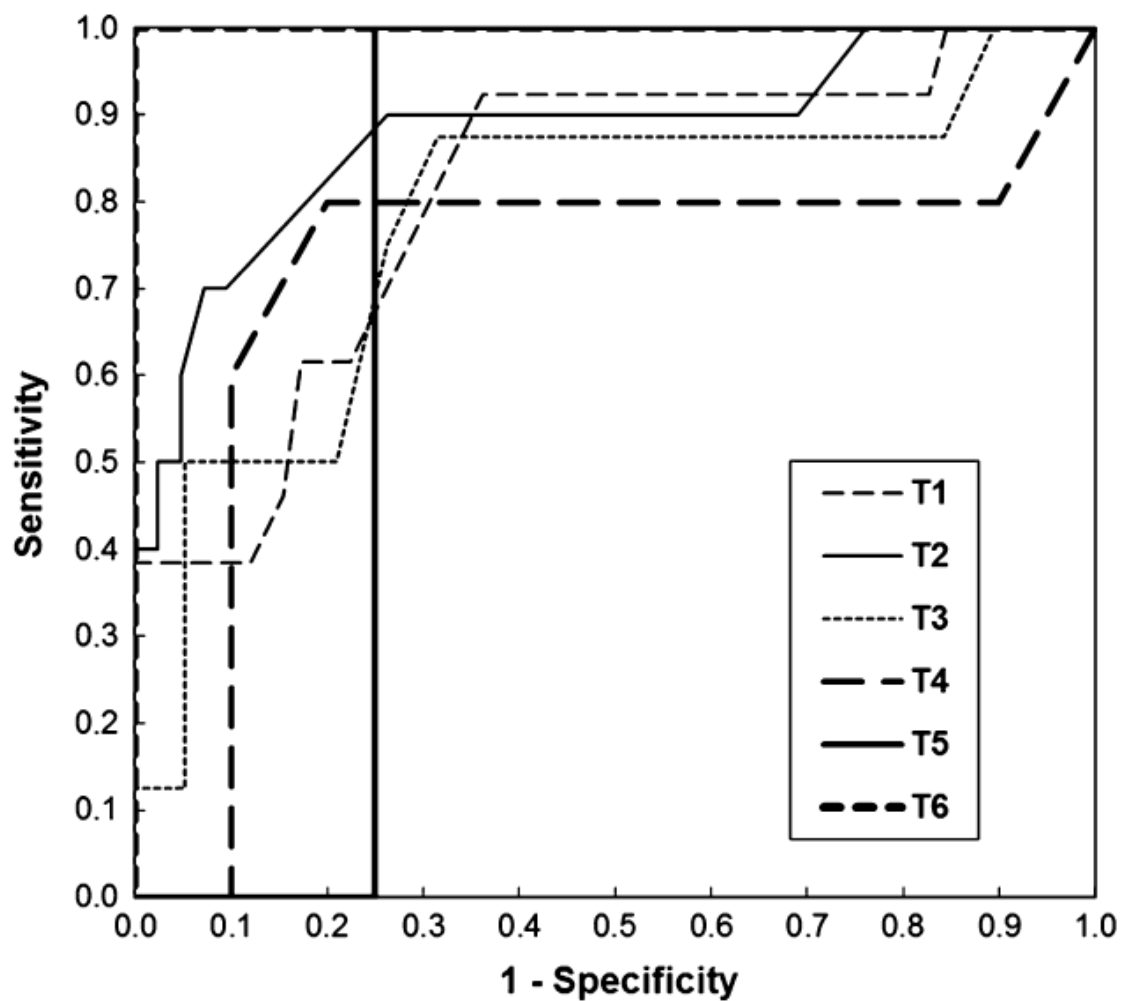


Figure 9. Receiver operating characteristic (ROC) curves on the accuracy of the fetal head-symphysis distance for predicting operative delivery at different scan intervals. T1 = scan at the beginning of the active second stage. Following scans are at 20 minute-intervals (T2, T3, T4, T5 and T6 at 20, 40, 60, 80, 100 min from the beginning of the active second stage).

Table 2: Receiver operating characteristic (ROC) curves for the fetal head-symphysis distance (HSD) at different scan intervals

	Area under the ROC curve (AUC±SE)	95% confidence interval	Cut-off (mm)	Sensitivity	Specificity	Positive predictive value	Negative predictive value
T1	0.810±0.068	(0.676-0.944)	17-18	12/13 (92.3%)	37/58 (63.8%)	12/33 (36.4%)	37/38 (97.4%)
T2	0.879±0.071	(0.739-1.018)	14-16	9/10 (90.0%)	31/42 (73.8%)	9/20 (45.0%)	31/32 (96.9%)
T3	0.776±0.108	(0.565-0.988)	12-13	7/8 (87.5%)	13/19 (68.4%)	7/13 (53.8%)	13/14 (92.8%)
T4	0.720±0.171	(0.385-1.055)	-	-	-		
T5	0.750±0.217	(0.326-1.174)	-	-	-		
T6	1.000±0.000	(1.000-1.000)	-	-	-		

T1 is the scan at the beginning of the active second stage. The following scans are at 20 minute-intervals (i.e., T2, T3, T4, T5 and T6 are at 20, 40, 60, 80, and 100 minutes from the beginning of the active second stage, respectively).

HSD yielded a significant prediction of operative delivery in the first three time-intervals with an AUC±SE value of 0.810±0.068 at T1, 0.879±0.071 at T2, and 0.776±0.108 at T3. The following values of sensitivities and specificities were obtained by using the best cut-off values: HSD values greater than 17 mm had a 92.3% sensitivity (12/13) and a 63.8% specificity (37/58) at T1; a cut-off of HSD ranging from 14-15 mm had a sensitivity of 90.0% (9/10) and a specificity of 73.8% (31/42) at T2; and HSD values greater than 12 mm had a sensitivity of 87.5% (7/8) and a specificity of 68.4% (13/19) at T3. Among these three time intervals (T1, T2, and T3), we could notice a trend towards a decreasing sensitivity and an increasing specificity with a more advanced stage of labor (Table 2).

The univariate logistic regression showed that HSD was significantly related to operative delivery (odds ratio (OR) 1.202; 95%CI: 1.115-1.296; $p < 0.001$). HSD was also found to be the unique significant variable independently associated with operative delivery among the three ultrasonographic parameters in the first multivariate logistic regression made, while HSD (OR=1.229; 95%CI: 1.133-1.332; $p < 0.001$) and epidural analgesia (OR=5.819; 95%CI: 2.086-16.234; $p=0.001$) were the only two variables maintaining a significant independent association with the operative delivery at the second analysis made among the overall set of ultrasonographic, maternal, and intrapartum variables. These data showed that the probability of an operative delivery increased by about 23% for each mm increase in HSD and increased about 6-fold with the administration of epidural analgesia. According to these values, the score computed by using these two variables was equal to $0.206 \times \text{HSD} + 1.761$ when epidural analgesia was administered. The accuracy of the score for predicting operative delivery was 0.830 ± 0.036 and the best cut-off (values ranging from 4.94 to 5.06) showed a sensitivity of 70.0% (28/40 women with operative delivery) and a specificity of 86.6% (116/134 women with spontaneous delivery). The accuracy of this score was comparable to that obtained by using the three variables significantly associated with operative delivery in the previous publication on the same population²³, namely angle of progression, maternal age and epidural analgesia (0.830 ± 0.036 vs. 0.819 ± 0.037 , $p = 0.831$). The score using the data of the previous publication was equal to $-0.055 \times \text{angle of progression} + 0.129 \times \text{years of maternal age} + 1.277$ in case of epidural analgesia was administered + a constant equal to 8). The best cut-off of the score calculated using only the data of the previous publication on the same population (value ranging from 5.25 to 5.29) showed a sensitivity of 87.5% (35/40 women with operative delivery) and a specificity of 67.2% (90/134 women with spontaneous delivery).

A graphic representation of the relation between the angle of progression and the fetal head-symphysis distance is displayed in figure 10, which demonstrated a significant ($p < 0.001$) linear

relation between the two parameters, both in cases with spontaneous vaginal delivery and those with operative delivery. In particular, the slope in operative deliveries was significantly higher ($p < 0.001$) than in spontaneous vaginal deliveries.

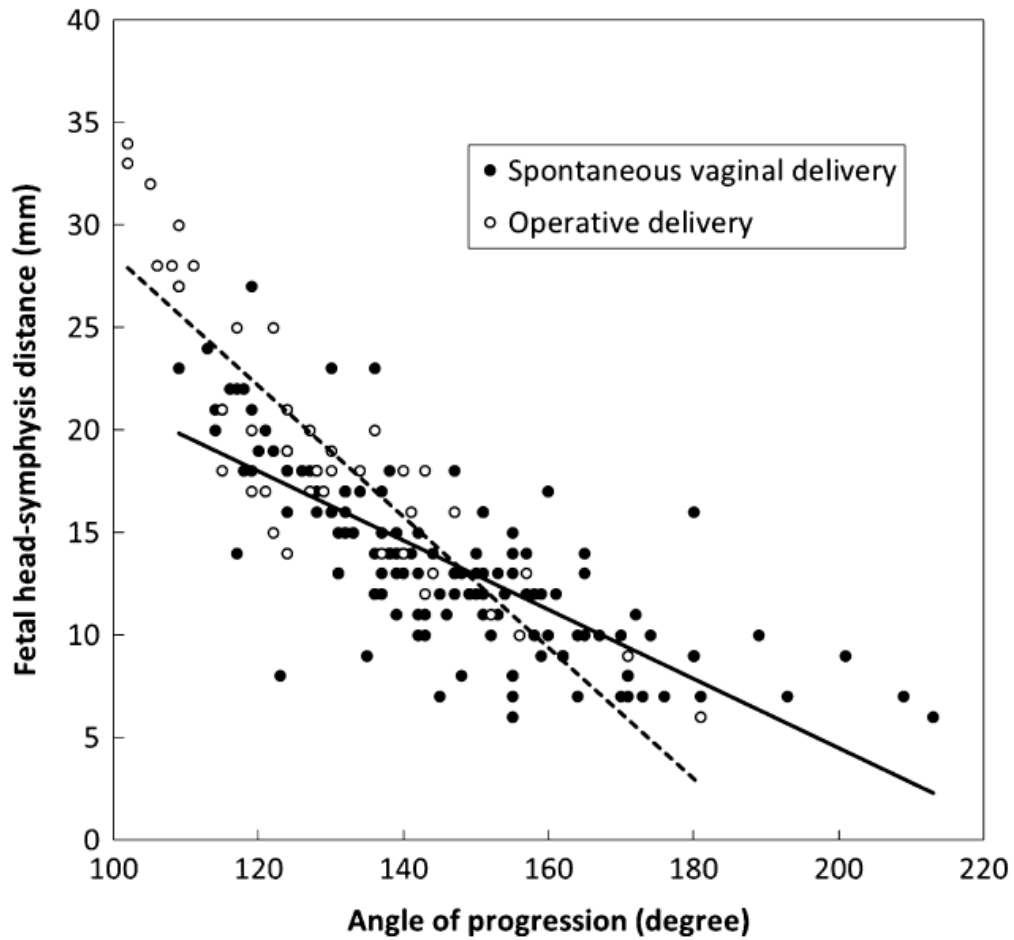


Figure 10. Graphic representation of the relation between the angle of progression (x-axis) and the fetal head-symphysis distance (y-axis) in women with spontaneous vaginal delivery (solid circles, solid trend line) and those with operative delivery (open circles, dotted trend line).

DISCUSSION AND CONCLUSIONS

Our study provides data on the use of a simple and reliable index of fetal head station in the active second stage. We demonstrated that HSD, an easily measured distance between the lower edge of the maternal pubic symphysis and the fetal head, is significantly greater at the beginning of the second stage and for up to 40 minutes into the second stage in women undergoing operative delivery. Our data suggest also that the HSD may play a predictive role for the mode of delivery in a critical phase of labor. The predictive role of HSD was maintained even after including maternal and intrapartum confounding factors. Only HSD and the use of epidural analgesia maintained an independent association with operative delivery in the multivariate logistic regression model. Using the latter two parameters, we were able to compute an easily calculable and accurate score for the prediction of the operative delivery in the second stage that allows the obstetrician to predict with an over 80% accuracy that a woman with a HSD greater than 24.3 mm without epidural analgesia, or a HSD greater than 15.7 mm if she had epidural analgesia, would have an operative delivery. The accuracy of this two-parameter score may be even higher than that calculated by using the three-parameter model presented in our previous publication²³.

The digital evaluation of the space between the symphysis pubis and the fetal skull has been previously described as an indirect clinical sign of fetal head engagement. The accuracy of this specific parameter has, however, not been systematically assessed. It is now well accepted that the clinical evaluation of fetal head progression is highly subjective and poorly reproducible¹. Digital assessment of fetal head station can be even more misleading in the second stage due to cranial bone molding and edema (caput succedaneum). The use of ultrasound has been proposed as a complementary tool in the labor ward in order to provide an objective and reliable assessment of fetal head station and position. Several indices for fetal head descent and rotation in labor have been

studied. These include the angle of progression, the fetal head progression distance, the fetal head direction, the ultrasonographic fetal head station, the fetal head-perineum distance and the midline angle¹⁰⁻¹⁶. However, the application of intrapartum sonography in everyday clinical practice remains limited. This seems to be due at least in part, to the technical difficulty in obtaining many of the parameters that have been proposed thus far. The main advantage of the HSD is its simplicity, as this is the distance between two easily identifiable landmarks in the midsagittal plane. Whether it is simpler than other parameters is, however, still to be investigated. In addition, as demonstrated by our results, HSD can be a predictor of the mode of delivery when measured in the active second stage.

We provided original data on the longitudinal modifications of this new ultrasonographic index of fetal head descent in the active second stage among a cohort of low-risk nulliparous women. Multiple logistic regression demonstrated that HSD performs better than two other previously studied sonographic measurements, such as the angle of progression and the midline angle. When HSD measurement is available, the other studied ultrasonographic parameters (angle of progression and midline angle), and most clinical variables such as oxytocin administration, maternal age and BMI, were also found to lose their influence in the prediction of the mode of delivery. Indeed, only HSD and epidural analgesia were found to be independently associated with the occurrence of operative delivery. In this study, the use of 3D ultrasound was necessary to allow measurement of different parameters for each volume, in a way where the observer was blinded to the progress of labor^{18,25}. We used the 3D technique because it permitted measurements on previously acquired volumes, obviating the need to recruit the same cohort twice. However, 3D ultrasound is not necessary to measure the HSD, which can be also easily obtained with standard two-dimensional sonography. Indeed, we have recently demonstrated that 2D and 3D techniques have excellent intermethod agreement for HSD measurement²⁶. Therefore, we think that both methods can be used interchangeably for this aim.

An interesting finding in our study was the significant difference encountered between the correlation curves of HSD and the angle of progression in women with spontaneous vaginal delivery compared to those with operative delivery (figure 10). The interpretation of this finding is not straightforward. However, we speculate that this difference may be the consequence of some grades of asynclitism or abnormal fetal head rotation (occipito-transverse or occipito-posterior), occurring more commonly in cases ending with operative delivery. These malpositions may have had a more pronounced and earlier effect on the extension movement rather than the descent of the fetal head. This may explain the finding that with narrower angles of progression (and thus higher fetal head station) the distance between the fetal skull and the maternal symphysis pubis (the HSD) was wider in cases with comparable values of angle of progression. Since in our study the fetal occiput position was not evaluated, our speculation cannot be confirmed by our data and needs further assessment.

We do acknowledge several limitations of our study. First of all, we had too few operative deliveries to permit us to perform a comparison between cases that underwent instrumental compared to cesarean delivery. In addition, the retrospective analysis of already available ultrasound volumes acquired as a part of another study did not allow us to perform a sample size calculation. Furthermore, we cannot provide data on the prediction of vacuum extraction failure as there were no such cases. However, we believe that HSD is a potential aid in identifying cases in which a vaginal extraction is possible and to distinguish those from cases in which a cesarean section would be preferable. This should be the subject of further studies. Another limitation is that, due to the relatively small population included, we had to perform the multivariate analysis by pooling the overall data of the acquired volumes in all time intervals. Therefore, we computed a unique score that was not stratified by the time elapsed from the beginning of the active second stage. Further studies aiming to prospectively validate the accuracy of this score during the course of the active second stage are required. Lastly, we chose to evaluate the fetal head progression in

the intervals between uterine contractions and maternal pushing efforts in order to avoid movement artifacts at the time of volume acquisition. It would be of interest to also investigate the dynamic effects of maternal pushing on the HSD.

In summary, the present study provides original data on the use of ultrasound in labor. A new simple intrapartum sonographic measurement, the fetal head-symphysis distance (HSD), may thus be useful predictor of operative delivery, even after considering other confounding factors.

REFERENCES

1. Dupuis O, Ruimark S, Corinne D, Simone T, Andre D, Rene-Charles R. Fetal head position during the second stage of labor: comparison of digital vaginal examination and transabdominal ultrasonographic examination. *Eur J Obstet Gynecol Reprod Biol* 2005 Dec 1; 123 (2): 193-7.
2. Akmal S, Kametas N, Tsoi E, Hargreaves C, Nicolaides KH. Comparison of transvaginal digital examination with intrapartum sonography to determine fetal head position before instrumental delivery. *Ultrasound Obstet Gynecol* 2003 May; 21 (5): 437-40.
3. Akmal S, Tsoi E, Nicolaides KH. Intrapartum sonography to determine fetal occipital position: interobserver agreement. *Ultrasound Obstet Gynecol* 2004 Sep; 24 (4): 421-4.
4. Akmal S, Kametas N, Tsoi E, Howard R, Nicolaides KH. Ultrasonographic occiput position in early labour in the prediction of caesarean section. *BJOG* 2004 Jun; 111 (6): 532-6.
5. Akmal S, Tsoi E, Howard R, Osei E, Nicolaides KH. Investigation of occiput posterior delivery by intrapartum sonography. *Ultrasound Obstet Gynecol* 2004 Sep; 24 (4): 425-8.
6. Sherer DM, Miodovnik M, Bradley KS, Langer O. Intrapartum fetal head position A: comparison between transvaginal digital examination and transabdominal ultrasound assessment during the active stage of labor. *Ultrasound Obstet Gynecol* 2002 Mar; 19 (3): 258-63.
7. Cunningham F MP, Gant NF, Leveno KJ, Gilstrap LC 3rd, Hankins GDV et al. Anatomy of the reproductive tract. In: Licht J e, editor. *Williams obstetrics*. Stamford (CT): Appleton & Lange; 1997.
8. Stovall BA, Kumar S. Anatomical landmark asymmetry assessment in the lumbar spine and pelvis: a review of reliability. *PM R* 2010 Jan; 2 (1): 48-56.
9. Barbera AF, Imani F, Becker T, Lezotte DC, Hobbins JC. Anatomic relationship between the pubic symphysis and ischial spines and its clinical significance in the assessment of fetal head engagement and station during labor. *Ultrasound Obstet Gynecol* 2009 Mar; 33 (3): 320-5.

10. Henrich W, Dudenhausen J, Fuchs I, Kamena A, Tutschek B. Intrapartum translabial ultrasound (ITU): sonographic landmarks and correlation with successful vacuum extraction. *Ultrasound Obstet Gynecol* 2006 Nov; 28 (6): 753-60.
11. Dietz HP, Lanzarone V. Measuring engagement of the fetal head: validity and reproducibility of a new ultrasound technique. *Ultrasound Obstet Gynecol* 2005 Feb; 25 (2): 165-8.
12. Ghi T, Farina A, Pedrazzi A, Rizzo N, Pelusi G, Pilu G. Diagnosis of station and rotation of the fetal head in the second stage of labor with intrapartum translabial ultrasound. *Ultrasound Obstet Gynecol* 2009 Mar; 33 (3): 331-6.
13. Eggebo TM, Gjessing LK, Heien C, Smedvig E, Okland I, Romundstad P et al. Prediction of labor and delivery by transperineal ultrasound in pregnancies with prelabor rupture of membranes at term. *Ultrasound Obstet Gynecol* 2006 Apr; 27 (4): 387-91.
14. Barbera AF, Pombar X, Perugino G, Lezotte DC, Hobbins JC. A new method to assess fetal head descent in labor with transperineal ultrasound. *Ultrasound Obstet Gynecol* 2009 Mar; 33 (3): 313-9.
15. Youssef A, Maroni E, Ragusa A, De Musso F, Salsi G, Iammarino MT et al. Fetal head-symphysis distance: a simple and reliable ultrasound index of fetal head station in labor. *Ultrasound Obstet Gynecol* 2013 Apr; 41 (4): 419-24.
16. Eggebo TM, Heien C, Okland I, Gjessing LK, Romundstad P, Salvesen KA. Ultrasound assessment of fetal head-perineum distance before induction of labor. *Ultrasound Obstet Gynecol* 2008 Aug; 32 (2): 199-204.
17. Tutschek B, Braun T, Chantraine F, Henrich W. A study of progress of labour using intrapartum translabial ultrasound, assessing head station, direction, and angle of descent. *BJOG* 2011 Jan; 118 (1): 62-9.

18. Molina FS, Terra R, Carrillo MP, Puertas A, Nicolaidis KH. What is the most reliable ultrasound parameter for assessment of fetal head descent? *Ultrasound Obstet Gynecol* 2010 Oct; 36 (4): 493-9.
19. Duckelmann AM, Bamberg C, Michaelis SA, Lange J, Nonnenmacher A, Dudenhausen JW et al. Measurement of fetal head descent using the 'angle of progression' on transperineal ultrasound imaging is reliable regardless of fetal head station or ultrasound expertise. *Ultrasound Obstet Gynecol* 2010 Feb; 35 (2): 216-22.
20. Bamberg C, Scheuermann S, Slowinski T, Duckelmann AM, Vogt M, Nguyen-Dobinsky TN et al. Relationship between fetal head station established using an open magnetic resonance imaging scanner and the angle of progression determined by transperineal ultrasound. *Ultrasound Obstet Gynecol* 2011 Jun; 37(6): 712-6.
21. Tutschek B, Torkildsen EA, Eggebo TM. Comparison between ultrasound parameters and clinical examination to assess fetal head station in labor. *Ultrasound Obstet Gynecol* 2013 Apr; 41 (4): 425-9.
22. Torkildsen EA, Salvesen KA, Eggebo TM. Prediction of delivery mode with transperineal ultrasound in women with prolonged first stage of labor. *Ultrasound Obstet Gynecol* 2011 Jun; 37 (6): 702-8.
23. Ghi T, Youssef A, Maroni E, Arcangeli T, De Musso F, Bellussi F et al. Intrapartum transperineal ultrasound assessment of fetal head progression in active second stage of labor and mode of delivery. *Ultrasound Obstet Gynecol* 2013 Apr; 41 (4): 430-5.
24. Nizard J, Haberman S, Paltieli Y, Gonen R, Ohel G, Le Bourthe Y et al. Determination of fetal head station and position during labor: a new technique that combines ultrasound and a position-tracking system. *Am J Obstet Gynecol* 2009 Apr; 200 (4): 404 e1-5.

25. Ghi T, Contro E, Farina A, Nobile M, Pilu G. Three-dimensional ultrasound in monitoring progression of labor: a reproducibility study. *Ultrasound Obstet Gynecol* 2010 Oct; 36 (4): 500-6.
26. Youssef A, Bellussi F, Montaguti E, Maroni E, Salsi G, Morselli-Labate AM et al. Agreement between two- and three-dimensional methods for the assessment of the fetal head-symphysis distance in active labor. *Ultrasound Obstet Gynecol* 2013 Sep 4.
27. Youssef A, Ghi T, Awad EE, Maroni E, Montaguti E, Rizzo N et al. Ultrasound in labor: a caregiver's perspective. *Ultrasound Obstet Gynecol* 2013 Apr; 41 (4):469-70.
28. Youssef A, Bellussi F, Maroni E, Pilu G, Rizzo N, Ghi T. Ultrasound in labor: is it time for a more simplified approach? *Ultrasound Obstet Gynecol* 2013 Jun; 41 (6): 710-1.
29. Kalache KD, Duckelmann AM, Michaelis SA, Lange J, Cichon G, Dudenhausen JW. Transperineal ultrasound imaging in prolonged second stage of labor with occipitoanterior presenting fetuses: how well does the 'angle of progression' predict the mode of delivery? *Ultrasound Obstet Gynecol*. 2009;33:326-30.